



## A 980nm Diode Laser Clot Formation of the Rabbit's Dental Sockets after Teeth Extraction

**Balsam M. Mirdan**

*Institute of Laser for Postgraduate Studies, University of Baghdad, Baghdad, Iraq*

(Received 7 July 2012; accepted 15 August 2012)

**Abstract:** The aim of this research work is to evaluate the use of 980 nm diode laser in clotting the blood in the bone socket after tooth extraction. The objective is to prevent possible clot dislodgement which is a defect that may lead to possible infection. A number of rabbits were irradiated using 980nm CW mode diode laser, 0.86W power output for 9s and 15s exposure time. The irradiated groups were studied histopathologically in comparison with a control group. Results showed that laser photothermal coagulation was of benefit in minimizing the possibility of the incidence of postoperative complications. The formation of the clot reduces the possibility of bleeding and infection.

### Introduction

One of most common causes of pain after 3-4 days of tooth extraction is dry socket (alveolitis simplex). Symptoms develop 10 to 40 days after tooth extraction. Dry socket may be defined as a postoperative pain surrounding the alveolus that increases in severity for some period from 1 to 3 days after extraction; partial or total clot loss in the interior of the alveolus, with or without halitosis follows that. (Blum 2002, Torres-Lagares 2005)

Microscopically, dry socket is characterized by the presence of inflammatory cellular infiltrate, including numerous phagocytes and giant cells in the remaining blood clot, associated with the presence of bacteria and necrosis of the lamina dura

(Faillo 1948). Regional lymphadenopathy may present in the affected side, and fever is infrequent. Dry socket is commonly observed in 40 to 45 years old patients (Rud 1970; Rood 1980), in an incidence of 1- 4% after teeth extraction, with an incidence for lower teeth 10 times greater than that for upper teeth (Alling 1993) reaching 45% for mandibular third molars (Butler 1971, Al-Khateeb 1991, Fazaker 1991, Trieger 1991, Blum 2002, Noroozi, 2009).

Blood clot formation is a fundamental step for the subsequent phases of tissue repair. The fibrin network allows invasion by fibroblasts, endothelial cells and macrophages, which are present in the remaining periodontal ligament. New fibroblasts is usually a characteristic of the granulation tissue. The macrophages are

essential for clot remission as this tissue undergoes maturation with the progressive apposition of collagen and production of bone matrix by osteoblasts (Okamoto 1994, Dvivedi 1997).

The application of 980nm wavelength diode laser was approved to be useful in blood coagulation and biostimulation of bone healing (Kathleen D., Fornaini C.). 600nm to 980nm diode lasers have energy per photon that is very poorly absorbed by hemoglobin, water, and other body pigments (Figure 1), this type of laser energy relies on a multiple pigment effect to produce a general tissue interaction (Noal 2006).

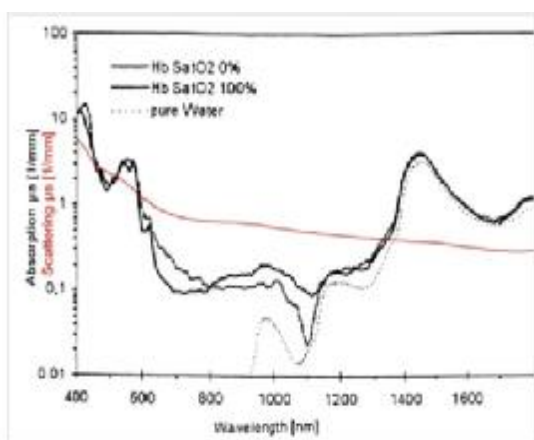


Fig. (1): Absorption and Scattering coefficients of blood relative to wavelength.

The present work involves a trial to obtain suitable laser parameters that can provide an immediate blood clot in the dental socket after extraction, without exposing the underneath bone to infection and delayed healing.

### Material and Method

Fifteen rabbits 4 months to 6 months of age were used as samples for this experiment. Each rabbit was anaesthetized using an intramuscular injection of (5 mg/kg) Zylazine in combination with (35 mg/kg) Ketamine (Donald 2005). The extraction of the lower left central incisor was done for each sample, the rabbits were divided into three groups; a control group; where the coagulation was done by pressing on the wound site with a cotton pellet for 20min. (the

conventional method), a second group; the socket was irradiated after tooth extraction for 9s exposure time, and a third group; the socket was irradiated after tooth extraction for 15s exposure time. The bone sockets of the second and third groups were exposed to the diode laser light while in the control group the coagulation was left to be formed. Samples were sacrificed according to the healing process schedule 24hour, 3 days and 10days after laser irradiation. Laser dose parameters as power density and exposure time were deduced out of a pilot study to coagulate rabbit blood in Dirham tubes. Spectroscopic analysis for the blood sample of the rabbit was performed before the selection of the suitable wavelength.

The laser used is a VELAS 60, China manufactured diode laser that emits at 980 nm wavelength. The laser was set to emit 76W/cm<sup>2</sup> power density in continuous mode of operation during the experiments. The serial histopathological sections were stained with hematoxylin and eosin using standard procedures, and then examined by light microscope (Olympus).

### Results

The rabbit blood spectra indicated a value for the absorbance of 3.6 at 980nm wavelength Figure 2.

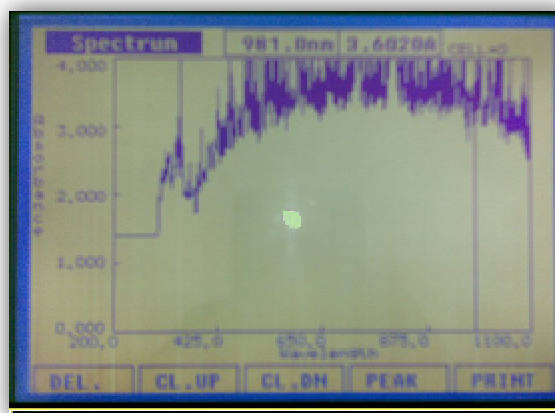
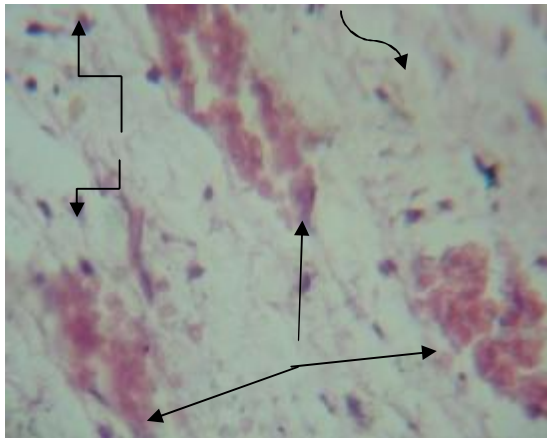





Fig. (2): Absorption spectra of the rabbit's blood for 980nm wavelength

Most of the extractions were not straight forward due to the rabbits lower jaw anatomy and the long cylindrical shape lower incisor.

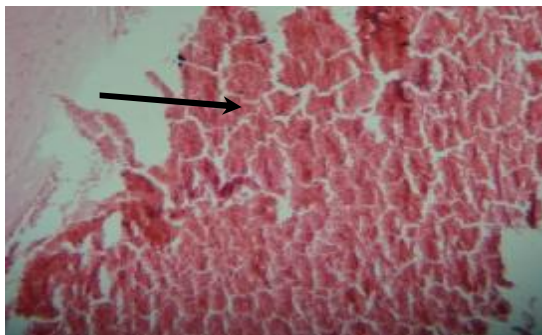Immediately after laser irradiation clotting of the blood in the socket was obvious. There was no sign of charring or bleaching at the peripheral border of the socket where the vital tissue present.




**Fig (3):** hisopathological section of the tooth socket for a rabbit (control) 3<sup>rd</sup> day proliferation of granulation tissue (  ) consisting of congested blood vessels (  ) with immature fibroblasts infiltration of inflammatory cells (  ). (H&E X400).

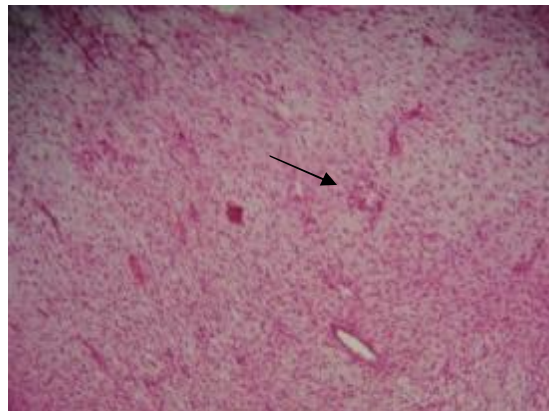
The results of the present study showed comparable (almost relative) histopathological features.


In control group the histopathological lesion on the first day was characterized by severe inflammation. There was an infiltration of inflammatory cells (neutrophils and macrophages) in addition to the blood coagulum which was extended cervically to fill the socket space. The coagulum was composed of densely aggregated red blood cells, platelets extended with presence of scavenger cells Figure 4.



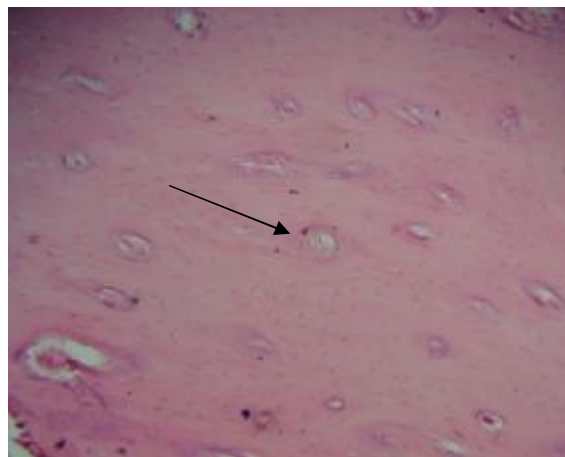
**Fig (4):** Hisopathological section of the tooth socket for a rabbit (control) first day showing severe hemorrhage (  ), (H&E stain X100).


On the third day there was a proliferation of granulation tissue consisting of congested blood capillaries with immature fibroblasts and infiltration of inflammatory cells (Figure 4). While on the 10<sup>th</sup> day there was infiltration of inflammatory cells at the periphery of the woven bone Figure 5.



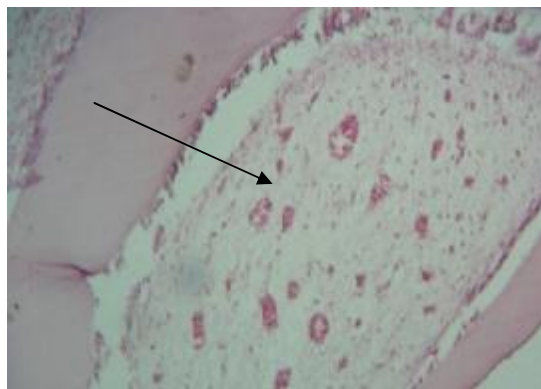
**Fig. (5):** Hisopathological section of the tooth socket for a rabbit (control) 10<sup>th</sup> day showing woven bone with infiltration inflammatory cells (  ). (H&E stain X100)

For the 9s exposure time group, histopathological changes started with inflammation and hemorrhage on the first day. The granulation tissue proliferation was seen on third day, while the organization of the mature bone appeared at day ten Figure 6.



**Fig (6).** Histopathological section of the tooth socket for a rabbit (9 s exposure time) 10<sup>th</sup> day showing mature bone characterized by trabeculae, lacunae in addition to osteocytes (  ). (H&E stain X100)

The histopathological picture of the 15s exposure time on the first day showed a variety of responses. The inflammation was noticed with granulation tissue (fibrous connective tissue). The organization of hemorrhage site was obvious as indicated in Figure 7. On the third day for the 15s exposure time group, mature bone appeared which was characterized by trabeculae, lacunae in addition to osteocytes; which were evident at the tenth day as shown in Figure 8.



**Fig (7):** Histopathological section of the tooth socket for a rabbit (15 sec exposure time) 1<sup>st</sup> day showing the granulation tissue and the organization of hemorrhage site ( —→ ). (H&E X400).

### Discussion

Different regions of the socket wall may experience different responses, depending on the trauma of the extraction. The bone health of the patient and to what degree the blood clot is retained. Independent of what is happening to the socket wall, if normal healing occurs, the fibrin clot will convert into granulation tissue and get organized into a collagen plug during the first month. This collagen plug will increase in density until it is gradually replaced from the apex and periphery by bone deposition.

Bone resorption was not noticed in the histopathology of the socket in control group and irradiated group. The sequel of the healing process of the bone socket was normal for the control group and 9s group in accordance to Boyne 1966.

In the case of the 15s exposure time group there was a progress in the organization of granulation

tissue and an early appearance of the bone trabeculae.

Biological tissue is a complex amalgam of connective tissue and cells. It contains light-absorbing elements known as chromophores, each of which absorbs light in a specific part of the electromagnetic spectrum. Examples of naturally occurring chromophores include melanin, hemoglobin, carotenoids, proteins, and water (Niems, 2003). A photon passing through the tissue generates no tissue effects until it is absorbed via rotation, vibration or electronic transition between energy levels by a wavelength specific chromophore. This process results in molecular excitation of the chromophore to a higher energy state. De-excitation of the chromophore releases this energy back into the tissue, causing tissue change through either photochemical or photothermal mechanisms (Niems, 2003). As light passes into matter, the direction of the incident rays is changed by the molecules present. Scattering plays an important role in the spatial distribution of the absorbed energy; it broadens the incident beam and eventually the deposited energy in the target area gets decreased.

Due to fluctuations in the refractive index of these media, the propagation of light into the tissue is modified and the scattering affects where the absorption will occur, usually reduce the penetration of light into the tissue. Heating decreases with tissue depth, as absorption and scattering attenuate the incident beam. At 940nm-980nm wavelength, scattering coefficient is  $0.6-0.64\text{mm}^{-1}$  and absorption coefficient  $0.25-0.28\text{mm}^{-1}$  in blood gives out an optical extinction coefficient of  $0.82-0.86\text{mm}^{-1}$  (Vuylsteke, 2009).

Those numbers prove that clotting was achieved in this research work due to absorption. Scattering was the factor that limits the laser photothermal effect to be conserved on the clot formation only, leaving the normal surrounding bone unaffected but instead its healing may be stimulated by the remaining scattered light from the incident laser.

### Conclusion

Using 15s exposure time with an output power of  $0.86\text{W}$  ( $76\text{W}/\text{cm}^2$ ) in CW mode of



operation stimulate and facilitate bone healing process, in addition to the 980nm effect to coagulate the blood to provide dressing to the wound side. The use of laser for clotting blood in dental socket after tooth extraction gives encouraging results in particular is the absent thermal trauma to the underlying bone or any sign of delayed healing.

### References

- Al-Khateeb TL, El-Marsafi AI, Butler NP, (1991): The relationship between the indications for the surgical removal of impacted third molars and the incidence of alveolar osteitis. *Oral Maxillofac Surg* 49:141.
- Alling CC III, Helfrick JF, Alling RD, (1993): *Impacted Teeth*. Philadelphia, WB Saunders.
- Blum I. R., (2002): "Contemporary views on dry socket (alveolar osteitis): a clinical appraisal of standardization, aetiopathogenesis and management: a critical review," *International Journal of Oral and Maxillofacial Surgery*, **31**, (3), pp:309-317.
- Blum IR (2002): Contemporary views on dry socket (alveolar osteitis): A clinical appraisal of standardization, aetiopathogenesis and management: A critical review. *Int J Oral Maxillofac Surg* 31:309.
- Boyne PJ (1966): Osseous repair of the postextraction alveolus in man. *Oral Surg Oral Med Oral Pathol* 21: 805-813.
- Breger Noel and H. Eeg Peter, (2006): *Veterinary Laser Surgery / A Practical Guide*, First Ed., Blackwell Publishing, chapter 3, 41.
- Butler DP, Sweet JB (1977): Effect of lavage on the incidence of localized osteitis in mandibular third molar extraction sites. *Oral Surg Oral Med Oral Pathol Oral Radiol Endod* 44:14.
- Dvivedi S, Tiwari SM, Sharma A., (1997): Effect of ibuprofen and diclofenac sodium on experimental wound healing. *Indian J Exp. Biol*; **35**:1243-1245.
- Faillo P S," Proteolytic enzyme treatment for the necrotic alveolar socket (dry socket)"*Oral Surg Oral Med Oral Pathol.*; **1** (7):608-131948
- Fazakerlev M, Field EA (1991): Dry socket: A painful post-extraction complication (a review). *Dent Update* 18:31.
- Fornaini C, Rocca JP, Bertrand MF, Merigo E, Nammour S, Vescovi P., (2007): Nd:YAG and diode laser in the surgical management of soft tissues related to orthodontic treatment. *Photomed Laser Surg. Oct*; **25** (5):381-92.
- Goharkhay K. , Moritz A. ,P. Wilder-Smith ,U. Schoop , Kluger W. , Jakolitsch S. , Sperr W. , (1999): Effects on oral soft tissue produced by a diode laser in vitro, *Lasers in Surgery and Medicine*,**25**, Issue 5, p. 401–406.
- Kathleen D. Gibson, Brian L. Ferris, Daniel Pepper, (2007): "Endovenous Laser Treatment of Varicose Veins" *Surg Clin N Am* **87**, 1253–1265.
- Niemz Markolf H. (2007): *Laser-Tissue Interactions Fundamentals and Applications Third Enlarged Edition*, Springer. P 1-79.
- Noroozi AR, Philbert RF, (2009): Modern concepts in understanding and management of the "dry socket" syndrome: Comprehensive review of the literature. *Oral Surg Oral Med Oral Pathol Oral Radiol Endod* 107:30.
- Okamoto T, Okamoto R, Alves Rezende MCR, Gabrielli MFR, (1994): Interference of the blood clot on granulation tissue formation after tooth extraction. *Histomorphological study in rats. Braz Dent J*; **5**:85-92.
- Pick RM, Colvard MD. Current status of lasers in soft tissue dental surgery. *J Periodontol.*; **64** :589–602.
- Plumb Donald C., (1993): *Veterinary Drug Hand book*, Fifth Edition, Blackwell publishing, P. 804.
- Rood JP, Danford M, (1981): Metronidazole in the treatment of "dry socket." *Int J Oral Surg* 10:345.
- Rud J, (1970): Removal of impacted lower third molars with acute pericoronitis and necrotizing gingivitis. *Br J Oral Surg* 7:153.
- Torres-Lagares, D., Serrera-Figallo, M. A., M. Romero-Ruiz M., P. Infante - Cossio, M. Garcia-Calderón, and Gutierrez Perez, J. L., (2005): "Update on dry socket: a review of the literature," *Medicina Oral, Patología Oral y Cirugía Bucal*, **10**, (1), pp. 77–85.

Trieger N, Schlagel GD, (1991): Preventing dry socket: A simple procedure that works. J Am Dent Assoc 122:67.

Vuylsteke M, Van Dorpe J, Roelens J, et al., (2009): Endovenous laser treatment: a morphological study in an animal model. Phlebology;24:16-75.

## تكوين الخثرة بالليزر للمقابس السنية بعد قلع الأسنان

بلسم محمد مردان

معهد الليزر للدراسات العليا ، جامعة بغداد ، بغداد ، العراق

**الخلاصة**  
الهدف من هذا العمل البحثي هو لتقييم إستخدام ليزر الدايبود ذي الطول الموجي 980 نانومتر بتخثر الدم في المقابس العظمية بعد قلع السن، لكي يمنع الإزاحة المتوقعة للخثرة الذي هو خلل من الممكن أن يؤدي إلى عدوى محتملة. عدد من الأرانب شععت باستخدام ليزر الدايبود ذي الطول الموجي 980 نانومتر بطراز الموجة المستمرة، 0.86 واط قدرة مخرجة ل9ثواني و15 ثانية زمتا للتعرض. المجاميع المشععة درست نسيجيا مرضيا بالمقارنة مع مجموعة السيطرة. نتائج أظهرت أن التخثر الضوئي الحراري بالليزر كان مساعدا لتقليل إمكانية حصول تعقيدات ما بعد العملية. تكوين الخثرة بالليزر في المقابس السنية بعد قلع السن هو طريقة عليا للعلاج التي من اللازم أن تأخذ بالإعتبار. تكوين الخثرة يقلل من احتمالية النزف والعدوى.