



Clinical Applications of a 940 nm Diode Laser for Laser Troughing Versus Conventional Method: A Preliminary Study

Humam Barrak^{1,*}, Shaimaa S. Mahdi², Salah A. Alkurtas³

¹*Institute of Laser for Postgraduate Studies, University of Baghdad, Baghdad, Iraq*

²*College of Science for Women, Baghdad University, Baghdad, Iraq*

³*Al-Turath University, Maxillofacial Consultant, Department of Dentistry, Baghdad, Iraq*

* *Email address of the Corresponding Author: drhumam08@gmail.com*

Article history: Received 11 Mar. 2024; Revised 7 May 2024; Accepted 2 Jun. 2024; Published online 15 Dec. 2024

Abstract

Background/purpose: Gingival troughing is the procedure of deflecting the marginal gingiva away from a tooth in order to provide a better visualization of the finish line. In this case report study, monitoring and assessment of the clinical outcomes of two gingival troughing techniques was conducted, also the patient satisfaction during application. Two techniques were applied: the traditional method (retraction cord) and the diode laser (940 nm) method which was compared in terms of bleeding, discomfort, and operating time.

Materials and methods: Three individuals who required two crowns on natural teeth on the same side were indicated. Before the treatment, the patient's gingival and periodontal health were healthy, and they showed no symptoms of gingival recession or inflammation. One tooth was selected randomly for conventional therapy utilizing a double retraction cord, while the other was treated with a 940nm diode laser. The teeth were prepared with a 0.5 mm sub-gingival finish line, and temporary crowns were made. Patients were followed at 48-72 hours and after 5 days. Operation time and hemorrhage scores were measured at the operation time while VAS score was measured after the complete cessation of the anesthetic effect at day zero and during the follow-ups. These measurements and patients' feedback provided valuable data for evaluating the effectiveness of both techniques in promoting healing and reducing post-operative complications.

Results: The tooth that received the laser treatment showed approximately no bleeding at the operation time, minimal time to complete the procedure and no pain. In all cases, results showed that laser treatment saved troughing time, it also revealed that laser treatment resulted in a reduced risk of infection due to its sterilizing effect.

Keywords: Diode laser, Gingival troughing, Laser therapy, Retraction cords, Soft tissues.

1. Introduction

The use of diode lasers in soft tissue surgery has gained much interest in literature [1, 2]. In recent years, there have been some alterations in the conventional approaches in dental practice due to the availability of new treatment equipment[3, 4]. The laser's action mechanism on tissue is determined by the laser settings



and the properties of the tissue[5]-[6, 7]. Different types of lasers have been used in soft tissue management like Nd:YAG laser, diode, CO₂, and Erbium laser family [8]. Laser application served as an adjunctive or alternative treatment option after considering conventional therapy, as a result of its variable peculiarities, including hemostasis [9], sterilization [10, 11], and ablation [12] or vaporization[13]. For that reason, the laser's coagulating effect is used because it can provide a gingival trough to aid in impression registration [14]. Gingival trough is the narrow space between the epithelium-free gingival margin and the adjacent tooth while gingival troughing is the procedure of deflecting the marginal gingiva away from a tooth,[15].

The process of preparing for a full crown frequently needs a subgingival placement of the finishing line may be due to the presence of caries, previous restoration, the need for additional retention or esthetic demand [16]. A detailed impression is required to seal the edge of the preparation accurately. Lateral and/or vertical gingival displacement, together with moisture control, is frequently required for registering the finish line after the preparation of the final impression [17]. The gap must be sufficiently large to accept adequate thickness of elastomeric impression material, which provides its strength to avoid tearing of the impression during removal and allows it to withstand deformation during the pouring of the impression [18]. Formerly, there were several ways for gingival troughing [19], including; mechanical methods with retraction cords or paste, chemo-mechanical methods with retraction cords soaked with a hemostatic solution, surgical techniques such as gingivectomy and laser surgery using different laser wavelengths. In this preliminary study, a comparison of two methods of gingival troughing was made using laser and retraction cords in terms of pain, bleeding, and operation time.

2. Materials and methods

This preliminary study compared the effect of laser surgery in gingival troughing to the traditional method of using retraction cords. The patients signed an informed consent form after receiving thorough information about the potential dangers and advantages. Three healthy volunteer patients were in good health and received the same treatment process, they needed crown restorations on two natural teeth on the same side. The selected teeth should not have any periodontal pocket surpassing 3 mm, and the treatment requires optimal gingival health. The patient was informed and agreed to the treatment plan. Then Informed Consent Form (ICF) was signed, and the treatment protocol was established to complete the treatment.

The teeth were prepared in a chamfer finish line around 0.5 millimeters positioned apically to the gingival margin during the first visit. The double-cord technique was used on one tooth and the laser treatment was used on the other.

For the trough prepared by the retraction cord method, the procedure started with the insertion of a number 000 cord (Ultrapak™ E Knitted Epinephrine Displacement Cord, Ultradent Products Inc, USA) at the base of the gingival sulcus using a blunt instrument. Next, a number 1 cord (Ultrapak™ E Knitted Epinephrine Displacement Cord, Ultradent Products Inc, USA) was placed to ensure the finishing line was visible. The first cord inserted remained in place for the entire recorded time, while the second cord was inserted for only 1-3 minutes to achieve the desired tissue displacement which was removed prior to taking the impression. For the laser troughing procedure, the gingiva was troughed using a 940nm diode laser (Epic, BIOLASE Technology, USA). Before beginning the operation, the optical fiber tip was initiated by burning pigment from the articulating paper on it. Then the laser was set at low power settings ranging from 1 to 1.3 W. In this case report, a 1W power in a pulsed mode was sufficient to achieve troughing in all the cases included, depending on the tissue type to reduce the risk of tissue charring. Since charring, is an adverse side effect that can occur during laser usage due to either moving the tip too slowly or using too much power.

To achieve troughing, the sulcular epithelium was removed by passing the tip along the gingival sulcus while facing away from the prepared tooth and toward the soft tissue. A full all-around trough was obtained by a constant and steady short brushing strokes which were used to remove the sulcus lining carefully [20]. To remove debris and avoid bacterial contamination, the tip was continually cleansed with gauze. The amount of excised epithelium was sufficient to allow for the impression material placement and to visualize the finish line. Figure 1 depicts teeth preparations and gingival troughing in all participants.



After the gingival troughing procedure, impression registration using a polyether impression material was done. Later on, it was poured with die stone to prepare the cast. Finally, Zirconia crowns were fabricated. The patient was followed at 48-72 hours and after 5 days.

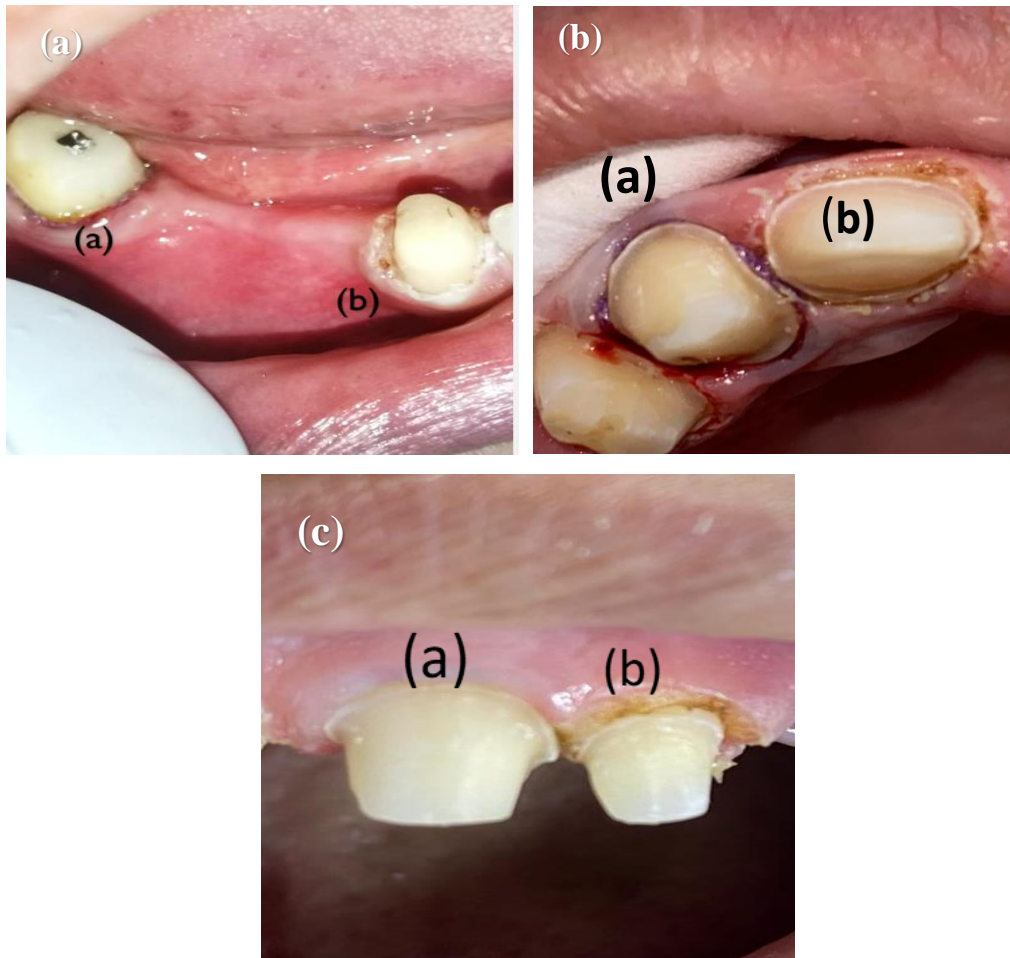


Fig. 1: Teeth preparations and gingival troughing for all the cases using (a) double-cord and (b) laser.

The time required to place and remove the retraction cord is recorded from the start of the procedure until the cord is removed while the laser troughing time is recorded from the start of the procedure until the impression is registered. Pain levels were assessed at the operation time using a visual analog scale (VAS), a pain scale assessment chart that can be printed and used so that adults and children can indicate the current intensity of pain they are experiencing [21]. Furthermore, the amount of hemorrhaging immediately following the removal of each retraction system was scored from 0 to 2 [22], as shown in table 2.

Table 1. Hemorrhage scores.

Score	
0	No bleeding
1	Controlled bleeding within 1 min
2	Uncontrolled bleeding within 1 min

3. Results and Discussion

The time taken for the retraction cord placement and for the laser troughing procedure was recorded as well as the time for the completed procedure which included both insertion and removal of the retraction cord together with impression registration for the traditional method group while for the laser group it includes only laser troughing with impression registration. The operation time for the laser troughing was considerably lower, with minimal patient discomfort. Table 2 shows the time needed for the gingival troughing process in seconds and for the completed procedure in minutes in both methods. The pain experienced during the process was recorded during treatment, and the VAS score was performed at the same session of finish line preparation after the complete cessation of anesthetic effect at day zero and during the follow-ups at 48-72 hours and after 5 days as shown in Table 3. It showed almost no pain in the laser-treated tooth compared to the conventional method in which the patient experienced discomfort. The bleeding tendency during the process was measured using a hemorrhage score that showed no bleeding during laser troughing when compared to the retraction cord process, which caused a slight hemorrhage, as shown in Table 4.

Table 2. Operation time.

Methods	Gingival troughing in seconds			The completed procedure in minutes		
	Case #1	Case #2	Case #3	Case #1	Case #2	Case #3
Retraction cord	182	185	186	11 min	12 min	13 min
Laser	17	16	16	8 min	7 min	7 min

Table 3. VAS score.

Follow-ups	Laser			Retraction cord		
	Case #1	Case #2	Case #3	Case #1	Case #2	Case #3
Day 0	1	1	1	4	6	3
Day 2-3	0	1	0	2	2	0
Day 5	0	0	0	0	0	0

Table 4. Hemorrhage score.

Methods	Hemorrhage score		
	Case #1	Case #2	Case #3
Retraction cord	1	2	0
Laser	0	0	0



4. Discussion

Retraction cords are the most widely used and popular method for gingival displacement. Although the retraction cord provides the intended retraction, it is a difficult approach that requires physical manipulation of the tissue, which might result in gingival bleeding [23]. Thus, using a retraction cord carries the risk of epithelial attachment injury and pain during cord installation, which may necessitate local anesthetic. Furthermore, additional time is necessary, and it may cause gingival bleeding and oozing [14]. Currently, laser applications are gaining much interest. One of the recent uses is for gingival troughing. Lasers remove the epithelial lining from the sulcus without damaging the tissue [20]. In the current preliminary study, we are exploring the use of soft tissue diode laser to counteract the disadvantages of the traditional method to achieve gingival displacement by comparing the two methods regarding operation time, pain, and hemorrhage. Table 2 shows that laser troughing reduced the total operation time by almost 50%, which is very beneficial for both the operator and the patient. This result came in agreement with Melilli et. Al., [24] who reported that diode lasers saved time compared to traditional retraction cords. The pain experienced by the patient in this study was recorded using VAS; the patient complained of discomfort during the insertion of the cord at the operation time and also complained of irritation at the follow-up visit after 48 hours; this result is similar to Einarsdottir et al., [25] who reported higher VAS levels in a randomized clinical trial of 67 individuals. However, VAS levels for the laser treatment showed almost no pain and discomfort due to the laser's ability to seal nerve endings [26]. The hemorrhage score demonstrated in Table 4 showed immediate hemorrhage for the retraction cord compared to the laser treatment that showed more control to hemorrhage as reported by Gururaj et. al. [27]. More clinical trials with larger samples are required to compare gingival displacement methods and produce more definitive results. Diode lasers are becoming more widely used as alternatives to electro-surgery systems and retraction cords, and this trend is set to continue in the future.

5. Conclusion

This study indicates that laser troughing saved time in minimizing operation time and ease of operation and did not cause bleeding. Additionally, the patient reported minimal discomfort, no pain and was more relaxed during troughing compared to the retraction cord placement.

Ethical approval

All procedures performed in the study involving human participants were in accordance with the ethical standards of the institutional and/or national research committee and with the 1964 Helsinki declaration and its later amendments or other comparable ethical standards.

References

- [1] R. Gounder and S. Gounder, "Laser science and its applications in prosthetic rehabilitation," *Journal of lasers in medical sciences*, vol. 7, p. 209, 2016.
- [2] A. I. Al-Khassaki, J. N. Ahmed, and A. S. Al-Allawi, "Histological Assessment of Anti-inflammatory Effectiveness of 940 Nanometer LLLT on Carrageenan Induced Arthritis in Temporomandibular Joint in Wistar Albino Rats," *Indian Journal of Public Health Research & Development*, vol. 10, 2019.
- [3] D. A. Almiran and S. A. Alkurtas, "A comparison between Er, Cr: YSGG 2780 nm laser and carbide fissure bur in root-end resection," *Iraqi Journal of Laser*, vol. 19, pp. 1-11, 2020.
- [4] R. A. Faris and A. Al-janabi, "Ultrafast lithium disilicate veneer debonding time assisted by a CO₂ laser with temperature control," *Optics Continuum*, vol. 2, pp. 825-837, 2023.
- [5] S. S. Mahdi, K. A. Aadim, and M. A. Khalaf, "New Spectral Range Generations from Laser-plasma Interaction," *Baghdad Science Journal*, vol. 18, pp. 1328-1328, 2021.



- [6] N. A. Dween, M. K. Dhahir, and T. N. Aldelaimi, "Evaluation of 940 nm Diode Laser in Esthetic Crown Lengthening," *Iraqi Journal of Laser*, vol. 22, 2023.
- [7] R. Hashim, M. Dhahir, and S. A. AlKurtas, "PDF Effectiveness of 980nm diode Laser in reduction the diameters of exposed dentinal tubules for hypersensitive tooth," *Iraqi Journal of Laser*, vol. 22, pp. 33-42, 2023.
- [8] F. E. Musaa, L. G. Awazli, and F. Alhamdani, "Gingival enlargement management using diode laser 940 nm and conventional scalpel technique (A comparative study)," *Iraqi Journal of Laser*, vol. 16, pp. 1-9, 2017.
- [9] N. A. Owaid, H. A. Jawad, and A. A. Maazil, "Evaluation of Low Level Laser Therapy using 785 nm Diode Laser on the Enhancement of Chronic Wound Healing," *Iraqi Journal of Laser*, vol. 15, pp. 41-46, 2016.
- [10] A. A. Shaheed, H. A. Jawad, B. Hussain, and A. M. Said, "Healing of Apical Periodontitis after Minimally Invasive Endodontics therapy using Er, Cr: YSGG laser: A Prospective Clinical Study," *Systematic Reviews in Pharmacy*, vol. 11, 2020.
- [11] N. M. Abdulmalek and M. K. Dhahir, "Laser Densification of Prepared SiO₂ Sol-Gel Thin Films," *Baghdad Science Journal*, vol. 15, pp. 0234-0234, 2018.
- [12] Z. J. Naeem, A. M. Salman, R. A. Faris, and A. Al-Janabi, "Highly efficient optical fiber sensor for instantaneous measurement of elevated temperature in dental hard tissues irradiated with an Nd: YAG laser," *Applied Optics*, vol. 60, pp. 6189-6198, 2021.
- [13] A. A. K. Aldelaimi, T. N. Aldelaimi, and S. M. Al-Gburi, "Using of diode laser (940 nm) in orofacial region," *Journal of Research in Medical and Dental Science*, vol. 5, p. 34, 2017.
- [14] V. Bennani, D. Schwass, and N. Chandler, "Gingival retraction techniques for implants versus teeth: current status," *The Journal of the American Dental Association*, vol. 139, pp. 1354-1363, 2008.
- [15] X. Tao, J.-W. Yao, H.-L. Wang, and C. Huang, "Comparison of Gingival Troughing by Laser and Retraction Cord," *International Journal of Periodontics & Restorative Dentistry*, vol. 38, 2018.
- [16] P. Łabno and K. Drobnik, "Comparison of horizontal and vertical methods of tooth preparation for a prosthetic crown," *Journal of Pre-Clinical and Clinical Research*, vol. 14, 2020.
- [17] B. Benson, T. Bomberg, R. Hatch, and W. Hoffman Jr, "Tissue displacement methods in fixed prosthodontics," *The Journal of prosthetic dentistry*, vol. 55, pp. 175-181, 1986.
- [18] S. A. Bernauer, J. Müller, N. U. Zitzmann, and T. Joda, "Influence of preparation design, marginal gingiva location, and tooth morphology on the accuracy of digital impressions for full-crown restorations: an in vitro investigation," *Journal of Clinical Medicine*, vol. 9, p. 3984, 2020.
- [19] K. D. Prasad, C. Hegde, G. Agrawal, and M. Shetty, "Gingival displacement in prosthodontics: A critical review of existing methods," *Journal of interdisciplinary dentistry*, vol. 1, pp. 80-86, 2011.
- [20] V. K. Ch, N. Gupta, K. M. Reddy, N. C. Sekhar, V. Aditya, and G. M. Reddy, "Laser gingival retraction: a quantitative assessment," *Journal of Clinical and Diagnostic Research: JCDR*, vol. 7, p. 1787, 2013.
- [21] O. Karcioğlu, H. Topacoglu, O. Dikme, and O. Dikme, "A systematic review of the pain scales in adults: which to use?," *The American journal of emergency medicine*, vol. 36, pp. 707-714, 2018.
- [22] A. Gupta, D. Prithviraj, D. Gupta, and D. Shruti, "Clinical evaluation of three new gingival retraction systems: A research report," *The Journal of Indian Prosthodontic Society*, vol. 13, pp. 36-42, 2013.
- [23] M. Thimmappa, M. Bhatia, P. Somani, and D. Kumar, "Comparative evaluation of three noninvasive gingival displacement systems: An in vivo study," *The Journal of the Indian Prosthodontic Society*, vol. 18, p. 122, 2018.
- [24] D. Melilli, R. Mauceri, A. Albanese, D. Matranga, and G. Pizzo, "Gingival displacement using diode laser or retraction cords: A comparative clinical study," *American Journal of Dentistry*, vol. 31, pp. 131-134, 2018.
- [25] E. R. Einarsdottir, N. P. Lang, T. Aspelund, and B. E. Pjetursson, "A multicenter randomized, controlled clinical trial comparing the use of displacement cords, an aluminum chloride paste, and a combination of paste and cords for tissue displacement," *The Journal of prosthetic dentistry*, vol. 119, pp. 82-88, 2018.
- [26] L. Walsh, P. L'Estrange, and G. Seymour, "High magnification in situ viewing of wound healing in oral mucosa," *Australian dental journal*, vol. 41, pp. 75-79, 1996.
- [27] R. Gururaj, S. Jayesh, and S. Nayar, "Comparative Evaluation of Four Factors in Gingival Retraction Using Three Different Gingival Retraction Techniques: In Vivo Study," *Indian Journal of Public Health Research & Development*, vol. 10, 2019.



التطبيقات السريرية لليزر الدايدود 940 نانومتر لحفر اللثة باستخدام الليزر مقابل الطريقة التقليدية: دراسة أولية

همام ثامر براك*¹، شيماء صالح مهدي²، صلاح عبد المهدي القرطاس³

¹معهد الليزر للدراسات العليا، جامعة بغداد. بغداد، العراق

²كلية العلوم للبنات، جامعة بغداد. بغداد، العراق

³جامعة التراث، استشاري جراحة الوجه والفكين، قسم طب الاسنان، بغداد، العراق

*البريد الإلكتروني للباحث: drhumam08@gmail.com

الخلاصة

الخلفية/الغرض: حفر اللثة هو ابعاد اللثة المحيطة بعنق السن بعيدا عن السن، من أجل توفير رؤية أفضل لتحضير السن من الجبهه الثوية. في هذه الدراسة ، تمت مراقبة وتقييم للنتائج السريرية لتقنيتين لحفر اللثة ، بلاضافة الى تسجيل تجربة المريض أثناء العملية. تم تطبيق تقنيتين: الطريقة التقليدية (سلك الازاحة) وطريقة ليزر الدايدود (940 نانومتر) و تمت مقارنتها من حيث النزيف ، وانزعاج المريض ووقت العملية.

المواد والطرق: حيث تمت الدراسة على ثلاثة أفراد بحاجة إلى تيجان على أسنان طبيعية على نفس الجانب. وتم اختيار افراد ذو لثة صحية، بدون أي أعراض لتراجع اللثة أو التهابها. تم اختيار التقنية بشكل عشوائي حيث عرض احد الاسنان للعلاج التقليدي، بينما تم علاج الآخر باستخدام ليزر الدايدود. تم تحضير الاسنان لاستقبال التيجان باستخدام قطر 0.5 ملم من جهة اللثة، وتم عمل تيجان مؤقتة. وكانت متابعة المرضى خلال 48-72 ساعة ومن ثم بعد 5 أيام. الوقت المستغرق لاتمام العملية ومقياس النزيف تم قياسه اثناء العملية في حين مقياس الالم تم قياسه اثناء العملية وخلال فترة المتابعة. تم اخذ النتائج والبيانات من اجل تقييم فعالية كلا التقنيتين في تسريع الشفاء والحد من مضاعفات ما بعد الجراحة .

النتائج: اظهرت النتائج ان الاسنان التي تلقت العلاج بالليزر لم يحدث فيها أي نزيف في وقت العملية، وقد استغرقت ايضا وقت اقل لإكمال العملية ولم يشكو المريض من الم. وفي جميع الحالات المعالجة، أظهرت النتائج أن العلاج بالليزر أدى إلى تقليل الوقت المستغرق لإكمال العملية، كما أن العلاج بالليزر يقلل من خطر الإصابة بالعدوى بسبب تأثيره التعقيمي المعروف. علاوة على ذلك، أظهرت الأسنان التي تلقت العلاج بالليزر وقت شفاء أسرع من الطريقة التقليدية.

