



## **Frequency Doubled Nd: YAG Laser for the Treatment of Diabetic Retinopathy**

**Nagham S. Al-Zubadi**

*Department of Ophthalmology, Medical College, Al-Mustansyria University, Baghdad, IRAQ*

**Abstract:** The present study was conducted with a view to determine whether focal laser therapy result in visual recovery and regression of macular edema in patients with non proliferative diabetic retinopathy and maculopathy ,and whether combined focal and scatter laser therapy in patients with proliferative diabetic retinopathy and maculopathy results in visual recovery ,regression of macular edema and regression of the risk factors. In the present work, a frequency doubled Nd: YAG laser was used for the treatment of diabetic retinopathy. The study evaluates 41 eyes of 33 diabetic patients both with Insulin Dependent Diabetes Mellitus IDDM, (n=16) and Non Insulin Dependent Diabetes Mellitus NIDDM, (n=17) with diabetic retinopathy divided into two groups. Maculopathy was regressed in 32/41 treated eyes, 23/24 with maculopathy and non-proliferative diabetic retinopathy are treated by grid laser photocoagulation, 9/17 with proliferative diabetic retinopathy and maculopathy are treated by grid combined with pan retinal photocoagulation. Maculopathy was unchanged in 7/41, deterioration in 2/41. Visual acuity improved in 8/41 patients one line of Snellen chart in young patients with shorter duration and non- proliferative diabetic retinopathy, and good visual acuity prior to therapy and 31/41 stabilized visual acuity for the follow up period, 2/41 deterioration of visual acuity by one line of Snellen chart with progression of edema, hemorrhage and exudation, 3/41 patients complain of paracentral scotoma one-week post treatment improved gradually after 2 weeks. Higher power density is needed to treat the diffuse form of maculopathy regarding the severity of maculopathy and macular edema. The power density needed to have the desired effect is less in more pigmented fundus than in fair fundus in order to have the same effect.

### **Introduction**

Diabetic maculopathy is one of the leading causes of reduced vision in cases of nonproliferative and proliferative diabetic retinopathy (Fredricks et al., 1987; Kaniski, 1990). Non proliferative diabetic retinopathy with maculopathy is generally treated with focal macular grid technique using the frequency – doubled Nd:YAG laser ,while in cases of proliferative diabetic retinopathy with maculopathy usually focal technique is combined with scatter therapy (Blankenship, 1988; Dastur, 1994; Little, 1985). The present study was conducted with a view to determine whether the focal laser therapy result visual recovery and regression of maculopathy and macular edema in-patients with non-proliferative diabetic retinopathy with maculopathy and to determine whether there is

visual recovery and regression of risk factor like neovascularization and macular edema. In patients with proliferative diabetic retinopathy with maculopathy treated by combined focal and scatter laser therapy (pan retinal photocoagulation), follow up period ranges from 6 - 8 months, to evaluate the visual recovery, regression of macular edema and occurrence of complication like decrease visual acuity, visual field loss, vitreous hemorrhage, and subsequent complications, e.g., tractional retinal detachment, rubeotic glaucoma, etc.. .

### **Materials**

The study evaluate 41 eyes of 33 diabetic patients both with Insulin Dependent Diabetes Mellitus IDDM (n=16), and Non Insulin Dependent Diabetes Mellitus NIDDM (n=17)

with Diabetic Retinopathy is, divided into two groups. The first group comprised of patients with nonproliferative diabetic with maculopathy (n=23) treated by grid retinal photocoagulation eyes. The second group with proliferative diabetic retinopathy with maculopathy (n=18) eyes treated by combined grid and pan retinal photocoagulation. Nineteen male and fourteen female patients Of age ranges from 20–75 years, duration of the disease ranges from 4–27 years (see Table 1), and the visual acuity ranges from 6/6 to 6/60

**Table 1:** Age and sex distribution of patients with non proliferative DR with maculopathy and proliferative DR with maculopathy

Age group	20–40 y	41–60 y	above 60 y
Male	3	13	3
Female	2	9	3
<b>total</b>	5	22	6

### Methods

#### Grid Retinal Photocoagulation

A Frequency doubled Nd:YAG laser is used for the treatment of maculopathy by Grid photocoagulation and clinically significant macular edema (Kaniski, 1990; Hersh, 1988; Saeed et al., 2001).

#### Indications:

(1) Thickening of the retina closer than 500 microns to the center of the macula, (2) hard exudates closer than 500 microns to the center of the macula associated with adjacent areas of retinal thickening, or (3) areas of retinal thickening larger than one disc diameter, any part of which is within one disc diameter of the center of the macula.

The wavelength of 532 nm of frequency doubled Nd:YAG laser is preferable for discrete areas of vascular leakage since it is absorbed by blood vessels. The image of fundus contact lens Mainster grid field laser lens is inverted. This laser lens burn size is approximately 1.05 times the spot size set on laser, such that 50 micron setting gives 52.5 micron true spot size.

#### The laser parameters:

The spot size of the laser beam ranges from 50

to 100 microns, with a duration of 0.05 to 0.1 s. The output power starts with minimal value 100 mW and can be adjusted as necessary to achieve a light to moderate intensity burn to produce a relatively burn without spreading of the spot apply 2 or 3 rows burn. The repetition rate was 1 Hz.

The power density was equal to  $4.62 \times 10^3$ ,  $6.93 \times 10^3$ ,  $9.24 \times 10^3$  and  $11.55 \times 10^3$  W/cm<sup>2</sup> for the power 100, 150, 200 and 250 mW respectively. The energy per pulse was equal to 10, 15, 20 and 25 mJ respectively.

#### Treatment schema:

The treatment schema is represented by the following steps:

(1) Confluent spots and multiple burns are applied over the same site as needed to obliterate focal areas of leakage. (Note that the density of burn may be varied depending on intensity of leak age always leaving at least one burn width between spots). The treatment may be extended out to two disc diameters from the center of the macula if necessary, but should not approach closer than 500 micron to the optic disc.

(2) Large areas of confluent treatment near the center of the macula shouldn't be applied to avoid development of paracentral Scotomata.

(3) Grid photocoagulation should be applied to diffuse areas of leakage, as

a- Thickened areas of diffuse leakage within two disc diameters should be treated, but not closer than 500 microns to the center of the macula.

b- Laser burns should be first applied to areas proximal to the foveal avascular zone.

c- 2 to 3 rows of burns should be applied.

Re-treatment of any focal areas of leakage is necessary if clinically significant macular edema persists. Moreover, additional grid photocoagulation may be applied to sites of diffuse leakage not originally treated.

#### Panretinal Photocoagulation

A Frequency doubled Nd:YAG laser is also used to treat proliferative diabetic retinopathy.

#### Indications:

Proliferative diabetic retinopathy with the following criteria:

(1) Neovascularization of the optic disc (NVD) or within 1 disc diameter of the optic disc, more than quarter disc area.

- (2) Any disc neovascularization in the presence of vitreous or preretinal hemorrhage.
- (3) Moderate to severe neovascularization elsewhere (NVE) in the presence of vitreous or preretinal hemorrhage (more than half disc area).

Fundus contact lens, Mainster wide field laser lens provide Fundus image over 125° image is inverted, burn size approximately 1.6 times the spot size set on laser (e.g., 500 micron setting gives approximately a 800 micron)

#### *The laser parameters*

The spot size of the laser beam ranges from 200-300 microns, 200 micron if treating within vascular arcades), with a duration of 0.1 – 0.2 seconds.

The output power (P) with a minimal value of 250 mW was adjusted as necessary to produce desired effect. The repetition rate ranges from 0.8- 1 Hz. The power density was  $3.73 \times 10^2$  W/cm<sup>2</sup>,  $6.22 \times 10^2$  W/cm<sup>2</sup> (P=300, 500 mW, s=200 micron set by device 320 micron). The power density  $2.76 \times 10^2$  W/cm<sup>2</sup> (P= 500 mW, s=300 micron set on device 480 micron). The energy per pulse was equal to 30 and 50 mJ in respectively.

#### *Typical treatment schema:*

The treatment schema is represented by the following steps:

- (1) 2500– 3000 spots applied over 2 to 3 sessions. Total number of spots and density of burns varies with clinical response to treatment, Separate sessions by approximately 3 weeks.  
In first session, a section of retina for treatment is selected. Approximately 600-800 evenly scattered spot and varying power are needed to obtain uniform burn intensity. In subsequent sessions, treat previously untreated region approximately 600-800 spots per session.
- (2) Space spots one burn width from each other.
- (3) Burns applied in peripheral area of relatively normal retina are tested to obtain baseline power for treatment and the laser power is adjusted to produce a gray-white (not intense white) burn.

#### *Notes:*

- Papillomacular bundle not to be treated.
- Areas closer than one-half diameter to

optic nerve head should not to be treated.

- Usually avoid treatment within arcades (may place a few spots just inside arcades if they are greater than 2 disc diameters from the fovea).
- Temporally, place 1 or 2 rows of burn 2 disc diameters from the fovea. (Areas nasal to this demarcation should not to be treated).
- Small areas of flat neovascularization elsewhere (NVE) may directly treated with confluent application of laser burns.
- Avoid treating disc neovascularization (NVD), areas of fibro vascular traction and over retinal vessels directly.

#### *Evaluation criteria*

We should emphasize that the main aim of our treatment is to preserve the patients' current visual acuity:

1. Best corrected visual acuity before treatment.
2. Best corrected visual acuity after treatment.
3. Slit lamp examination.
4. Tonometry: examination of intra ocular pressure.
5. Fundoscopic examination: examination of the retina under full pupillary dilatation (direct and indirect ophthalmoscope).
6. Slit lamp biomicroscopy examination.  
*Note:* Slit lamp biomicroscopy of posterior retina is the best method for detecting and evaluating macular edema. Diabetic maculopathy was diagnosed by ophthalmoscopic evidences of microaneurysms, retinal hemorrhages, exudates, venous looping or beading and intra retinal microvascular anomalies. The proliferative diabetic retinopathy was diagnosed by ophthalmoscopic evidence of neovascularizations at disc or elsewhere and sign of DM described above).
7. Visual field testing by Gold man perimetry.

*Note:* Flurescein angiography is a significant diagnostic tool but unfortunately not available.

Follow up first post operative day, then 3 weekly interval with all the above evaluation criteria, follow up from 6 - 8 months.

## **Results**

Maculopathy was regressed in 32/41 (78.04%) treated eyes, 23/24 95.8% with maculopathy and non- proliferative diabetic

retinopathy treated by grid laser photocoagulation 9/17 (52.94%) with proliferative diabetic retinopathy and maculopathy treated by grid combined with pan retinal photocoagulation (Fig. 1).

Maculopathy was unchanged in 7/41 (17.07%) and deterioration in 2/41 (4.87%) (Figs. 2 and 3).

Visual acuity improved in 8/41 (19.5%) patients' one line of Snellen chart in young patients with shorter duration and non-proliferative diabetic retinopathy and maculopathy. 31/41 (75.6%) stabilized visual acuity for the follow up period. 2/41 (4.87%) deterioration of visual acuity by one line of Snellen chart with progression of edema, hemorrhage and exudation (Figs. 3 and 5).

Regression of neovascularization of optic disc occurs within two months of treatment, microaneurysms, exudates and hemorrhage found to be disappeared after 6 months.

Laser lesions were detectable by biomicroscopy immediately after photocoagulation as grey white blenching. After one day the laser spots appear as yellow sites similar in appearance to drusen, after a period longer than three weeks, most lesions were regularly undetectable by ophthalmoscope or biomicroscopy. Occasionally some laser lesions were seen as hyperpigmented areas after three months (Table 3).

This treatment leads to reduction of leakage of fluid and hard exudates. It is known that even with laser photocoagulation microaneurysms in diabetic retinopathy are not directly influenced because the laser power is far to low to occlude them directly (Ovalero, 2001). 3/41 (7.3%) patients complain of paracentral scotoma one week post treatment were improved gradually after 2 weeks. This may be due to sub clinical macular edema occurs after laser photocoagulation (Tsuji-kawa et al., 1999). One patient has aqueous flare 10 days after treatment (Table 2). A Significant increase in permeability of blood-aqueous barrier is noticed after pan retinal photocoagulation for proliferative diabetic retinopathy (Lill-Inger and Nulja, 2001).

Deterioration was additionally predicted by maculopathy with proliferative diabetic retinopathy, increase age, NIDDM, lower visual acuity prior to treatment.

Higher power density is needed to treat the diffuse form of maculopathy regarding the severity of maculopathy and macular edema,

Also power density needed to have the desired effect is less in more pigmented fundus than in fair fundus in order to have the same effect. Eyes with psuedophakia need less power than eyes with cataract.

Patients treated do not notice any restriction in visual fields in every day life, including when reading or watching television, suggesting that they are unaware of these field alterations.

**Table 2:** Complications post treatment

Complications	No. of patients	Time of appearance
Paracentral scotoma	3	1 week post treatment
Aqueous flare	1	10 days post treatment

**Table 3:** Laser lesions seen ophthalmoscopically post laser therapy

Time post treatment	Lesions appearance
Immediately after treatment	Grey white blenching
First day post treatment	Yellowish sites similar to drusen
> 3 weeks	Lesions undetected ophthalmoscopically
3 months and above	Occasionally laser lesions seen as hyper pigmented

**Table 4:** Response to laser therapy

Maculopathy	Visual acuity
32 regressed	8 improved
7 unchanged	31 stabilized
2 deterioration	2 deterioration

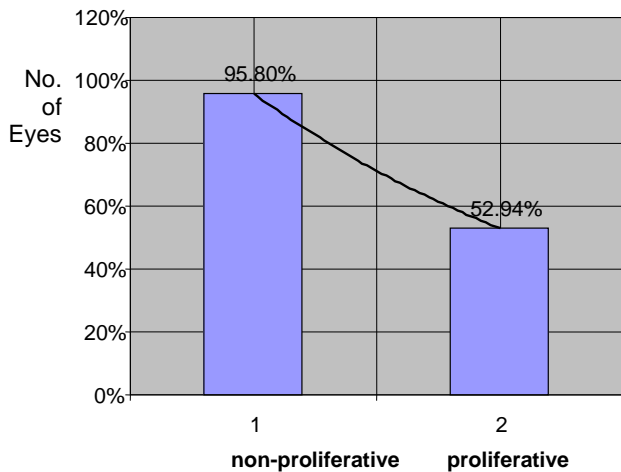


Fig. 1: Maculopathy regression after laser treatment

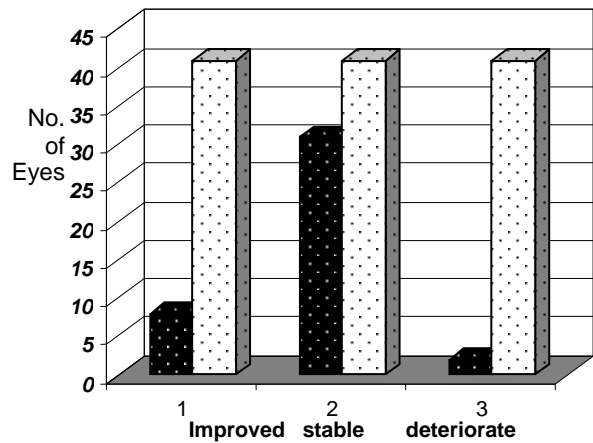


Fig. 4: Visual acuity after laser photocoagulation

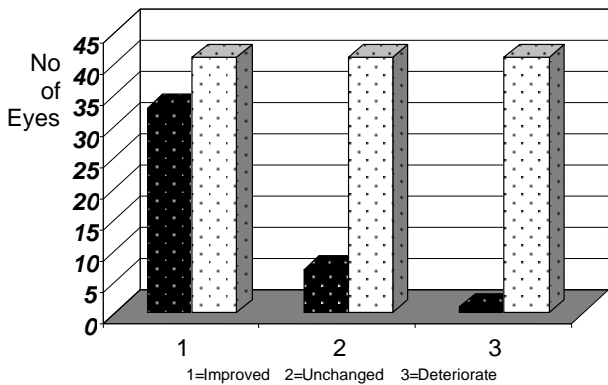


Fig. 2: Maculopathy result after laser photocoagulation

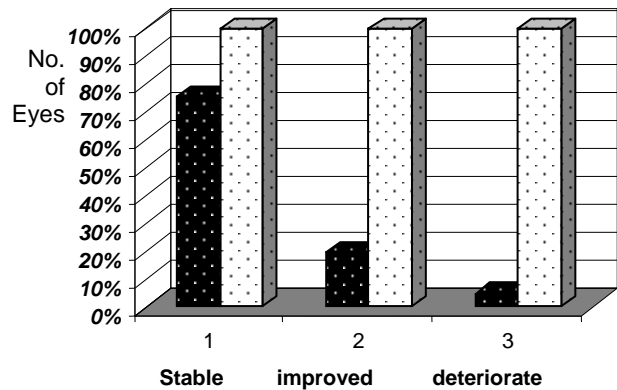


Fig. 5: Visual acuity result after laser photocoagulation

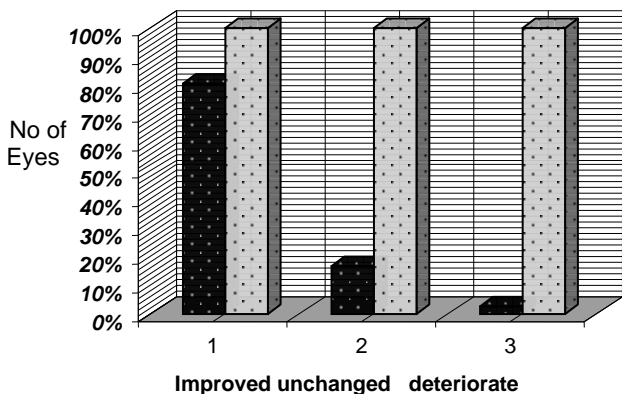


Fig. 3: Maculopathy result after laser photocoagulation

### Discussion

Diabetic maculopathy is an important cause of visual loss in eyes with both non-proliferative and proliferative diabetic retinopathy. Treatment with frequency doubled Nd: YAG laser facilitates improvement of visual acuity as it causes regression of macular edema, in the first group treated by Grid laser photocoagulation.

For the second group which treated by combined Grid and pan retinal photocoagulation facilitate improvement of visual acuity also facilitates regression of new vessels at disc and new vessels elsewhere. Also facilitate regression of edema, and it reduction the chance of sever visual loss due to vitreous hemorrhage, subsequent complications including tractional retinal detachment and neovascular glaucoma.

Although clinical trials have documented the efficacy of PRP its mechanism is not clear, one theory proposes that PRP destroys some of ischemic retina, thereby reducing its production of an angiogenic factor .A second theory suggests that PRP improves oxygenation of the ischemic inner retina by destroying metabolically active photoreceptor cells and allowing diffusion of oxygen from the choriocapillaries to inner retinal layers (Amatsubara et al., 2001)

A 532 nm Nd: YAG laser is preferred because it has good hemoglobin absorption in retinal blood vessels and causes minimal damage to the macular xanthophyll and retinal nerve fiber layer.(Karacorlu et al., 1993) This study shows that the frequency doubled Nd:YAG laser is effective in treatment of diabetic maculopathy, improving visual acuity and decreases the complication.

When parts of peripheral retina are destroyed by photocoagulation, it is expected that both field of vision and night vision will be affected to some extent. The reasons why patients do not usually feel the difference after treatment are as follows:

1. Spots of photocoagulation scars are so distributed to leave functioning retinal areas all over the treated area thereby minimizing the effect of field defects
2. The retina with diabetic retinopathy has poor sensitivity as a part of disease. Therefore, the selective destruction of their poorly functioning retina is not as it would have been in a normal retina (Yoon, 1996).

This study coincides with similar studies done using frequency-doubled Nd:YAG laser (Saeed et al., 2001 ) argon ion laser (488 and 514 nm) (Dastur, 1994; Blankenship, 1988; Little, 1985), krypton red and dye yellow 577 nm (Karacorula et al., 1993), micropulsed and continuous 810 nm diode laser to treat the diabetic maculopathy (Friberg, and Kratza, 1997; Olk and Akduman, 2001).

In order to prevent hazardous situation during the job, many safety measures were taken into account in work.

### Conclusion

The study shows that in patients with non-proliferative diabetic retinopathy focal macular grid therapy using frequency doubled Nd:YAG

laser is clinically facilitates improvement of visual acuity as it causes a regression of macular edema .

In patients with proliferative retinopathy combined focal and scatter retinal photocoagulation facilitates regression of neovascularization and macular edema .Further it reduces the chances of sever visual loss due to vitreous haemorrhage, and its subsequent complications.

### References

- Amatsubara J.,Ylam S, Katic D.E., Gabelt B.T., Nork M., Paul L. and Kaufman (2001) *The effect of pan retinal photocoagulation in the primary visual cortex of adult monkey.* Tr oph Soc. **99**, 33- 43.
- Blankenship G.W. (1988) *Clinical comparison of central and peripheral argon laser pan retinal photocoagulation for proliferative diabetic retinopathy,* Ophthalmology **95**, 70- 76
- Dastur Y. K. (1994) *The Rational of Argon Green Photocoagulation For Diabetic Maculopathy,* Journal of Postgraduate Medicine **40**, 13 - 17.
- Fredricks F.I., Marvin P.J., Mathew D.D. (1987) *Macular Edema in diabetic retinopathy study patients: Diabetic retinopathy study report.* Ophthalmology **94**, 754- 66.
- Joseph R. O, Akduman L. (2001) *Minimal intensity diode laser (810 nanometer) photocoagulation (MIP) for diffuse diabetic macular edema,* Seminars in Ophthalmology, Vol.16, No.1, pp. 25-30
- Kaniski J.J. (1990) "Clinical Ophthalmology" Chap. 12, pp. 463- 79.
- Karacorlu S., Burumcek E., Kuraculu M. and Arslan O. (1993) *Treatment of diabetic macular edema:comparism between argon& dye laser Argon green and dye,* Turk. Ann. Ophthalmol. **25**, 138- 41
- Lill-Inger and Nulja E. (2001) *Increased permeability of the blood –aqueous barrier after PRP for PDR,* Acta Ophthalmologica Scandinavica **79**, 414
- Little H.L. (1985) *Treatment of proliferative diabetic retinopathy long term results of argon laser photocoagulation,* Ophthalmology **92**, 279- 83
- Ovalero S. (2001) *Retinopathy, Diabetic, Background.* Medicine ophthalmology, July 11.

- Peter S.H. (1988) "Ophthalmic Surgical Procedure", Chap. 9, pp. 385- 97
- Saeed M., Parmer D. and MeHugh D. (2001) *Frequency-doubled Nd:YAG laser for the treatment of exudative diabetic maculopathy*, Eye **15**, 712- 8
- Tsusikawa A., Jindong K.J., Tsutomu, Yasukawa, Izumisvma and Ogura Y. (1999) *Quantitative analysis of diabetic macular edema after scatter laser photocoagulation with scanning retinal thickness analyzer*, Retina **119**, 59- 64
- Yoon Y.H., Jikim Y.J., Korean J. (1996) *Preservation of retinal sensitivity in central visual field after pan retinal photocoagulation in diabetes*, Ophthalmol. **10**, 48- 54.
- Zalaski S., Marcil, L. L. (1986) *Study of visual field using automated static perimetry following pan retinal photocoagulation in diabetes*, J. Fr ophthalmol. **9**, 395- 401.

## علاج استحالة الشائبة الصفراء لداء السكري باستخدام ليزر النديميوم ياك ذي التردد المزدوج

نغم سلمان الزبيدي

قسم طب وجراحة العيون، كلية الطب، الجامعة المستنصرية، بغداد، العراق

**الخلاصة** تناقش الدراسة مدى فعالية وفائدة علاج استحالة الشائبة الصفراء لداء السكري بالليزر وبنوعي العلاج الموضوعي والشامل للشبكية في السيطرة على النضوح حول الشائبة الصفراء وتحسن الرؤيا وتقليل المضاعفات الناتجة عن المرض. شملت الدراسة 41 عينا لـ 33 مريضا، عولج القسم الاول موضعياً، فيما عولج القسم الثاني بالطريقتين الموضوعية والشاملة معا. نتيجة العلاج كانت كالآتي: فيما يخص الودمة، 41/32 عين كان هناك استجابة للعلاج وقلّة الودمة وتحسن الحالة المرضية، 41/7 عين بقيت الحالة مستقرة دون تغيير، 41/2 عين ساءت الودمة. اما ما يخص درجة الرؤيا فكانت كالآتي 41/31 عين كانت درجة الرؤيا ثابتة دون تغيير، 41/8 عين تحسنت درجة الرؤيا بمقدار خط واحد عن درجة الرؤيا السابقة، 41/2 هبطت درجة الرؤيا فيها خطأ واحداً مما كانت عليه قبل العلاج.