



## Carbon Dioxide Laser Treatment of Viral Warts: A New Approach

Muhsin A. Al-Dhalimi

Department of Dermatology, College of Medicine, Kufa University, Kufa, IRAQ

### Abstract:

**Objective:** Verrucae vulgares are commonly encountered. The present work is designed in an attempt to build a systematic procedure for treating warts by carbon dioxide laser regarding dose parameters, application parameters and laser safety.

**Patients and Methods:** The study done in the department of dermatology in Al-Najaf Teaching Hospital in Najaf, Iraq. Forty-two patients completed the study and follow up period for 3 months. Recalcitrant and extensive warts were selected to enter the study. Carbon dioxide laser in a continuous mode, in non-contact application, with 1 mm spot size was used. The patients were divided into two groups. The first group of patients consisted of 60 lesions divided to 6 equal groups, in whom we use different outputs and two modes of application (helical and radial) to assess the optimal power density and the best mode of application. The second group consisted of 75 lesions treated with output of 10 W continuous mode using helical mode of application.

**Results:** The optimal power was found to be 10 W. In the second group of patients, after 1 - 6 passes of laser (median 2.8 pass), complete clearance of the lesion was noticed in 56 lesions with a cure rate of 74.6%. This was found in 32 (68%) recalcitrant lesions and 24 (85.7%) lesions that had no previous treatment. The main complications were scarring in 17(22.5%) lesions and hyperpigmentation in 7 (12.5%) lesions. Post-operative infection was noticed in 4 (6%) lesions that were larger than 2 cm in diameter.

**Conclusion:** Carbon dioxide laser therapy of recalcitrant and extensive viral warts should be considered as a viable alternative to other more traditional techniques. This treatment offers good results in eliminating the verrucae and minimizing the squeals of recurrence, scarring and the post-operative pain.

### Introduction

Viral warts are benign hyperplastic growth of the epithelium caused by Human papillomas virus infection. The majority of cutaneous warts will regress spontaneously within 3 months to 5 years of their onset (Williams et al., 1993). This may occur within 2 years in 60% of the cases. There remain a small group of otherwise normal people whose warts persist for prolonged periods, sometimes many years. These may be a source of considerable discomfort and embarrassment to the patients.

Various conventional treatments have been employed to deal with these lesions. The treatment include destructive techniques such as curettage, cautery, surgical excision, and

cryotherapy, immunostimulation like levamisole, Cimetidine and dintrochlorbenzene sensitization, virucidal agents like glutaraldehyde or formaldehyde, and the use of Intralesional agents such as Bleomycin or interferon- $\alpha$  (Sterling and Kurtz, 1998). The long list of treatments available is an indication of the refractory nature of some warts.

Warts that fail to respond to conventional treatment have been considered as recalcitrant. In the last years, there have been many reports from different areas of the world concerning the use of the carbon dioxide laser to deal with such lesions (see Table 1).

Carbon dioxide laser emits a coherent light in the infrared region- 10600nm- that is specifically absorbed by water which constitutes 80% of the

**Table 1:** The results of different studies using CO<sub>2</sub> laser for treating warts

Author (s) and year of publication	Number and type of lesions	Laser parameters	Cure rate
Scott, 1984	Condylomata accuminata	NA	98%
McBurney and Roson, 1984	27 patients with recalcitrant or widespread warts	15 W CW 1 mm spot	81%
Logan and Zachary, 1989	22 patients with recalcitrant warts	20 W CW	56%
Apfelberg et al., 1989	25 patients (common warts)	NA	52%
Landsman et al., 1991	Recalcitrant plantar warts	NA	75%
Street et al., 1991	24 lesions, 17 patients, Recalcitrant verrucae	NA	71- 94%
Sloan et al., 1998	200 patients, Resistant verrucae	NA	64.1%
Tackae, 2000	Verrucae vulgaris	15 W superpulsed, pulsed and CW	NA
Savoca et al., 2001	80 patients, venereal warts	16- 18 W CW	87.5%
Lauchli, 2003	13 patients, immunosuppression	NA	12/13 improved 6 full recovery
Serour et al., 2003	40 patients, 54 recalcitrant warts	5 W superpulsed	100%

skin components. We use it in the non-contact mode to vaporize the warty tissues layer by layer.

The present work is designed in an attempt to build a systematic procedure for treating warts by carbon dioxide laser regarding dose parameters, application parameters and laser safety.

### Materials and Methods

This study was done in the out-patient clinic in the department of dermatology, Al-Najaf teaching hospital.

Forty two Patients with extensive or recalcitrant warts were selected for carbon dioxide laser therapy. Extensive refers to more than five lesions, or lesions larger than 2 cm in diameter. Warts were considered recalcitrant if they persisted for at least 12 months and were

unresponsive to at least one conventional treatment modality such as local acid application, electro-surgery, simple surgical excision or cryosurgery (McBurney and Roson, 1984)

The important parameters that are taken in consideration were:

1. Age of the patient.
2. Duration of the lesion.
3. Site of the lesion.
4. Number of the lesions: single versus multiple.
5. Whether the laser treatment is the first time treatment of the lesion or second type of treatment and the lesion was recurrent or unresponsive to previous treatment.

### Procedure:

Carbon dioxide laser, continuous mode (Blitz 50, ASA medical laser, Italy, 1998) was used. The characters of the device included:

### 1. CO<sub>2</sub> laser source

Wavelength; 10.6  $\mu\text{m}$   
Divergence; 2 mrad  
Output beam diameter; 1 mm (Focused hand- piece)  
Output mode; TEM<sub>00</sub>  
Output power level in CW mode; 1- 50 W  
Step 1 W

### 2. Helium-Neon laser (aiming beam)

Wavelength; 632.8 nm  
Divergence; 2 mrad  
Output beam diameter; 0.61 mm  
Output power level; 1 mW

The areas of involved tissues were cleaned with povidone iodine solution 10% and infiltrated locally with 2% xylocaine hydrochloride without adrenaline with the patient recumbent. The keratotic component of the wart, if present, was pared with a scalpel blade, in thin layers, taken care to avoid bleeding which would cause the laser light to be absorbed by surface blood. The hyperkeratotic surface is removed because this protinaceous debris requires much higher energy to vaporize because of its low water content and has a tendency to act as heat sink with resultant thermal diffusion. Paring allows deeper penetration of the laser beam into the wart tissue. Magnifying lens (2.5X magnifying loupes) was used during the treatment in order to see all small satellite warts and to judge more precisely when all wart tissue has been vaporized.

The laser light applied in non-contact method either in helical pattern from outside inward with the hand-piece moving at a rate of 1cm/s. or radially across the lesion in the same rate.

After each pass the resultant char was removed by gentle scrubbing with a cotton wool swab soaked in 3% hydrogen peroxide solution. This procedure was continued until all visible signs of wart tissue had been removed and the dermal rete ridges pattern was restored.

The assessment of wart removal was facilitated by fact that viral tissue bubbles and spatters under the laser in a manner quite different from the melting and contraction demonstrated by the surrounding dermal connective tissue. An average of four passes of the laser was required to remove the warts. The first pass of the laser included a zone

approximately 5 mm wide beyond the visible edge of the wart, as papillomas virus has been demonstrated in apparently normal epidermis surrounding viral warts (Logan and Zachary, 1989).

Post operatively, the treated areas were cleaned twice daily with 3% potassium permanganate (1/10000) and covered with a thin layer of gentamicin cream (Genedine cream, SDI) under non-adherent dressing until re-epithelization had taken place.

The study was divided into two parts:

#### Part 1:

In the first part, the lesions were divided into 6 groups; each one consists of 10 lesions, according to the laser output power and geometry of application:

- Group 1: laser output = 5 W, helical application.
- Group 2: 5 W, radial application.
- Group 3: 10 W, helical application.
- Group 4: 10 W, radial application.
- Group 5: 15 W, helical application.
- Group 6: 15 W, radial application.

#### Part 2:

In this part, and according to the results of Part 1, the remaining lesions and some of the recurrent lesions of the first part of the study were treated with laser output power of 10 W and a power density at the tissue level of 1000 W/cm<sup>2</sup> using the helical method of application as it is much easier.

Nineteen patients had warts at distant sites which were not treated and left as control.

#### Assessment:

The patients were seen on the next day looking for early post-operative complications and then followed up at approximately 2-weekly intervals for 4 - 6 weeks. The patients were asked to come 3 months after the operation. Complete cure was considered when the wart is completely eradicated and did not recur with restoration of normal skin markings. The treatment failure was considered when the wart is persisted, only partially removed or if the warty tissue recurs in or at close vicinity of the treated site during the follow up period.

Any associated complications like infection, scarring, hyperpigmentation, hypopigmentation or any other sequel were looked for. Essential

safety measures were undertaken through out the operation.

A statistical analysis had been done using Chi-square test at  $\alpha = 0.05$

## Results

Forty two patients with 113 lesions completed the period of follow up. There were 25 (59.5%) males and 17 (40.5%) females. The age of the patients ranged from 11- 37 years with a median of 14.7 years.

The lesions were distributed mainly in the upper and lower extremities (Table 2).

Specific symptoms that bring the patients to the hospital were pain or discomfort in the wart site in 28 patients, cosmetic embarrassment in 21 patients and orthopedic complications in 3 patients. Some patients, of course, had more than one cause that brings him to hospital.

In 25 (63%) patients, other modalities of treatment have been used and fail to eradicate the warts. The treatments included local acid application, electrocautery, surgical excision and cryotherapy (Table 3). Seventeen (37%) patients have extensive warts with no history of previous treatment; twelve patients of them have single lesions more than 2 cm in diameter.

In the first part of the study, the cure rate and the incidence of scarring were as presented in Table 4. According to these results, the power in the second part of the study was fixed at 10 W. The helical mode was chosen as it is easier technically.

In the second part of the study, 75 lesions were treated including the recurred lesions in the first part of the study. There were 47 (62.6%) recalcitrant lesions not responded to previous conventional treatments and 28 (37.4%) lesions with no previous treatment. The duration of the lesions prior to laser therapy ranges from 7 months to 15 years with a median of 2.5 years.

After 1- 6 passes of laser (median 2.8 pass), complete clearance of the lesion was noticed in 56 lesions with a cure rate of 74.6% (Figs. 1- 6). This was found in 32 (70%) recalcitrant lesions and 24 (85.7%) lesions that had no previous treatment. The differences appear to be not statistically significant ( $p > 0.05$ ).

Regarding the site of the lesions, plantar warts showing the lowest cure rate of 66%, while those on the arms and legs showing the

best cure rate, 100% and 85.7% respectively. The cure rates of the lesions on the hand and rest of the foot were comparable (Table 5).

Nineteen lesions (25.4%) showed recurrence. The warty tissues recur within the first 2 - 4 weeks. The healing usually occurs by granulation tissue formation. This takes between 2 - 8 weeks depending on the size of the lesion with a median of 5.6 weeks.

We compared clearance of the lesions with their size, of the warts that completely cleared, 35 (62.5%) lesions were less than or equal to 5 mm in diameter and 21 (37.5%) lesions were greater than 5 mm. Thirteen (68.5%) lesions of those that did not respond to CO<sub>2</sub> laser were greater than 5 mm and 6 (31.5%) lesions were less than or equal to 5 mm. These differences were not statistically significant ( $P > 0.05$ ).

Scarring in the treated areas was apparent in 17 (22.5%) lesions. In 3 (17.7%) cases the scars were tender on digital pressure. The scars were stubble and flexible in 16 (94.1%) lesions (Fig. 7) and hypertrophic in one (5.9%) lesion. The scars were located on the hands in 14 (82.3%) lesions while they present on the foot in 3 (17.7%) cases. The difference was highly significant ( $P < 0.05$ ). The development of the scars was not influenced by the duration of the lesions, size of the lesion, or the number of the passes of laser used.

Pain was experienced after laser treatment in 35 (83.3%) patients. It was mild that don't interfere with the patient activity and don't necessitate medication in 20 (57.1%) patients, moderate- relieved by simple analgesics in 11 (31.4%), and severe -prevent the patient from going to his work for few days in 4 (11.4%) patients.

Hyperpigmentation was noticed in 7 (12.5%) lesions. It was transient and disappears at the end of follow up period, except in one patient. Two lesions (3.57%) get persistent hypopigmentation.

Post-operative infection was noticed in 4 (6%) lesions that were larger than 2 cm in diameter. The infection treated effectively by addition of systemic antibiotic ciprofloxacin 500 mg twice daily.

Untreated warts at distant sites were not seen to resolve at the end of follow up period even after the successful eradication of warts at treated sites.

**Table 2:** Distribution of the lesions

Site	Extensive	Recalcitrant	Total
Hands	17	25	42
Foot: Plantar	5	8	13
Others	11	17	28
Arms and legs	9	21	30
Total	42	71	113

**Table 3:** Treatments used on 25 patients prior to CO<sub>2</sub> laser.

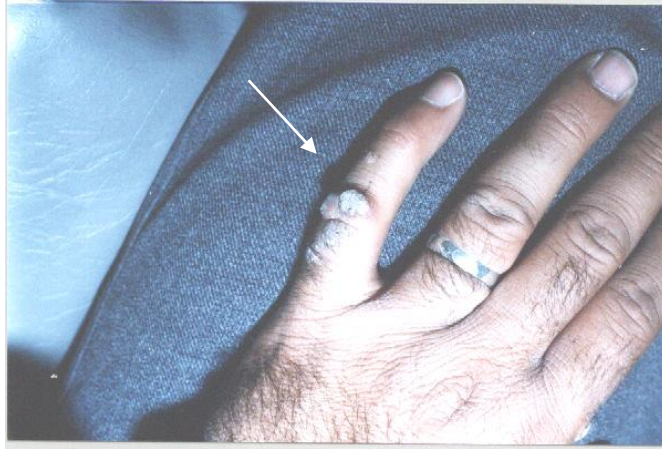Previous treatment	Number and Percentage
Local acid application	9 (36 %)
Electrocautery or Electrodesiccation	13 (52%)
Surgical excision	5 (20%)
Cryotherapy	2 (8%)

**Table 4:** The cure rate and the incidence of scarring for each group

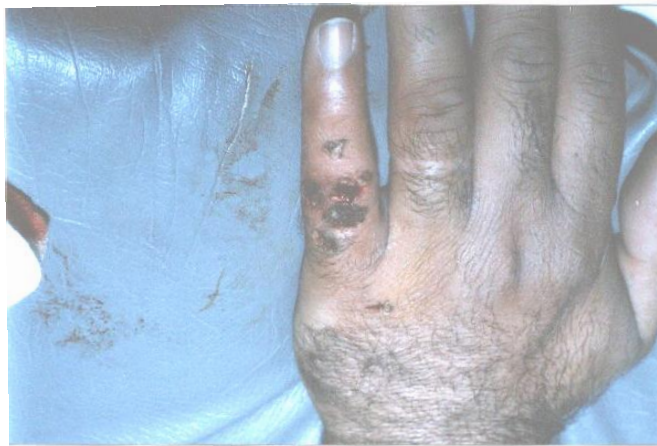Group Number	Cure Rate %	Scarring %
1	50	0
2	40	10
3	80	20
4	70	20
5	80	50
6	90	50

**Table 5:** Response of 75 viral warts to CO<sub>2</sub> laser therapy.

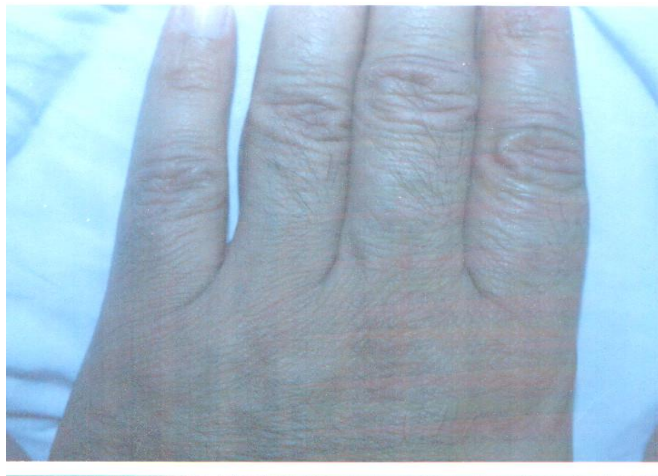Site	Extensive			Recalcitrant		
	Treated	Eradicated	Percentage	Treated	Eradicated	Percentage
Hands	11	10	90.9	16	11	69.9
Foot: Plantar	3	2	66.6	7	4	57.5
others	9	7	77.7	10	7	70
Arms and legs	5	5	100	14	12	85.7
Total	28	24	85.7	47	32	70



**Fig. 1** Recalcitrant warts on the dorsum of the fingers

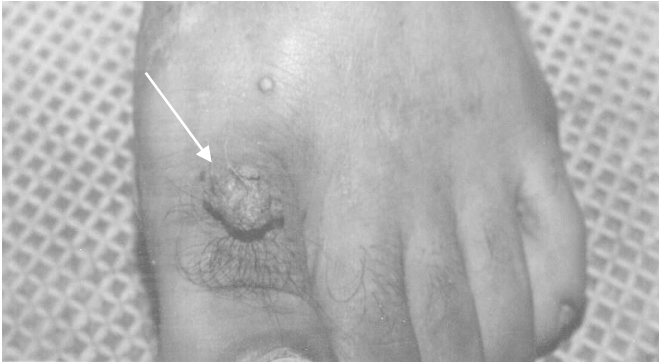

**Fig 2** The same area in Fig. 1, immediately postoperatively

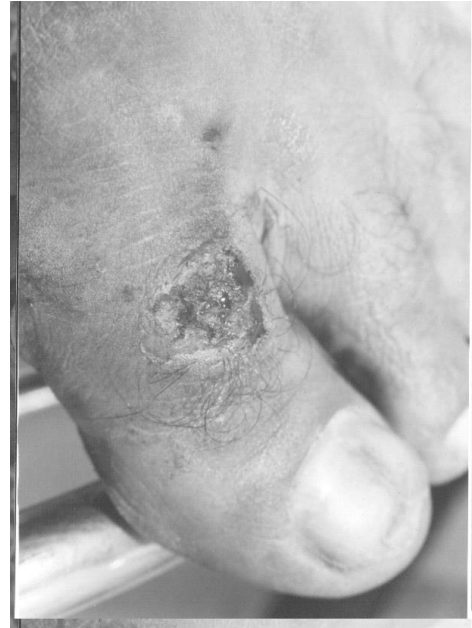

**Fig 3 :** The same area in Fig. 1, three months after CO<sub>2</sub> laser treatment. ``

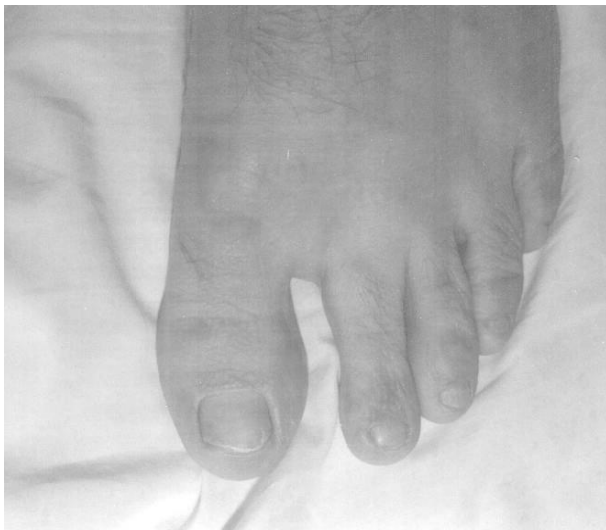



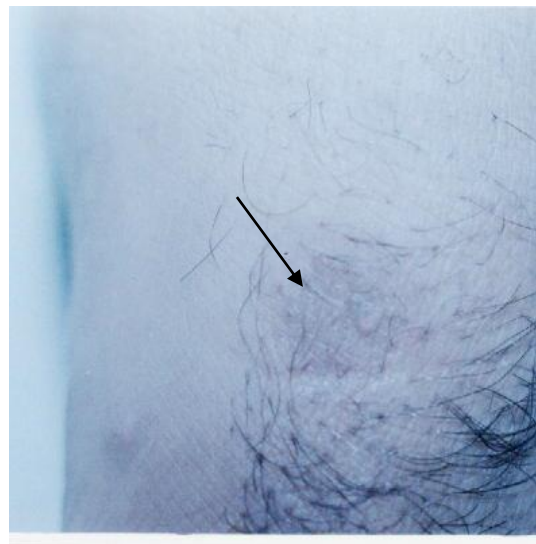
**Fig. 4:** Recalcitrant lesions on the dorsum of the foot.



**Fig. 5:** The same area in Fig. 4, immediately postoperatively.



**Fig. 6:** The same area in fig. 4, but 3 months after the CO<sub>2</sub> laser treatment.



**Fig. 7:** Atrophic flexible scar at the site of treated wart.

## **Discussion**

In the first part of the study we follow a new approach that – to the best of our knowledge – not tried previously. This help us to choose the most optimum power density at the tissue level that is associated with the highest cure rate and the lowest incidence of complications. Previous studies either fix the laser output power to certain value randomly or applied it within a limited range according to the wart size with spot size varied from 1 to 6 mm i.e., great variation in the power density. In spite of the relatively few number of the lesions in each group in this part of the work, a good idea can be calculated by looking at the results of this part. Accordingly, power density of 10,000 W/cm<sup>2</sup> was used in the rest part of the study. The results of the use of radial and helical mode of application were comparable. We choose the helical mode as it is easier technically.

The comparison of the two modes of applications, assessment of the most suitable power density, in addition to the measurement and fixation of the speed of the movement of the probe had not been published previously.

In the second part of the work, we had achieved a cure rate of 74.6% of viral warts. However, there were a disturbing number of complications especially post-operative pain in 83.3% of the patients and scarring in 22.5% of the lesions.

Previous workers in this field have produced more optimistic findings (Table 1), with cure rate of plantar warts ranging from 55% to 95% (Borovoy, 1987) and 64% to 100% of other types.

The difference in the results of different works may be attributed to differences in the patient selection, characters of the lesions, different criteria were used for describing simple and recalcitrant warts i.e. duration and previous treatment modalities, operative technique and after care.

The warts in this work had been present for a median period of 2.5 years, when the rate of spontaneous remission must be low (Williamm et al (1993). There is no doubt that more than half of the lesions represent a highly selected group with the most resistant warts. Previous articles give little information on this point, except for Borovoy's study where most of the treated lesions had been present for one year or less and for Logan and Zachary (1989) work, where the warts had been present for a median

period of 5 years. Although the recalcitrant lesions showing less cure rate than extensive lesions with no previous treatment but the difference is not statistically significant. Some of the previous showed that the recalcitrant lesions are more resistant to laser therapy (Logan and Zachary, 1989; Scott and Castro, 1984), while other study shows the reverse (Kenton-Smith and Tan, 1999).

Anatomic location did affect the cure rate. The lower cure rate of plantar warts is probably a problem that is associated not only with laser therapy but with other forms of treatment (Sterling and Kurtz, 1998; Borovoy, 1987). This is probably attributed to the resistant nature of the virus strains that are commonly associated with plantar warts, or due to thicker skin layers on the plantar surface the necessitate deeper penetration of the laser light. The more extensive nature of the mosaic plantar warts may let small islands of warty tissues that are not vaporizes and be a source of recurrence at or in immediate vicinity of the previous lesions.

Paring of the excess hyperkeratotic tissue from the wart surface prior to laser therapy will have debulked the wart, thereby reducing the total exposure required. Although debulking of the tissue by curettage have been mentioned either before (Borovoy, 1987) or after (Apfelberg et al., 1989) laser application, Paring is much better because it avoid expression of blood -as in curettage- that interferes with tissue vaporization. This paring may help to overcome the problem of the effect of the size of the warts on the laser output required for its vaporization (Logan and Zachary, 1989). In this study, although there is a trend for better cure rate in small lesions, the difference is not statistically significant. This makes us able to fix the laser output power during treatment of all lesions regardless of their size.

The use of magnifying lens helps in delineation of the wart tissue, and thereby, minimizing inadvertent laser light damage to the surrounding normal tissues. This will improve the cure rate by vaporization of all warty tissues and, at the same time, minimize the incidence of complications.

Scarring have been stressed upon only in two previous studies, where it happen in half of the lesions treated for finger warts in one work (McBurney and Roson, 1984) and in 60% of the lesions in another one (Logan and Zachary, 1989). We reported a lower incidence of scarring of 22.5%. This is probably related to



the choosing the most optimum laser output power utilizing the results of the first part of the study in addition to clearer vision during the operation by using the magnifying lens and the vacuum extractor that remove the vapor that may interfere with vision of the operative field. These help more identification of the warty tissues and reducing the damage to the surrounding tissues. The significantly lower incidence of scarring on the foot lesions is difficult to be explained except to note that the epidermis of the plantar surface of the foot is much thicker than that of the skin of the rest of the body. This makes the reaching of the thermal damage of the laser to the deeper layers of the reticular dermis- that may cause scarring- less likely.

In spite of the fact that post operative pain was reported by 83.3% of the patients, it was significant and interferes with the patient work in 11.4% of the patients only. This goes in agreement with many works (McBurney and Roson, 1984; Scott and Castro, 1984; Landsman et al., 1992; Sloan et al., 1998; Takac, 2000), apart from one study that show post-operative pain in all patients (Logan and Zachary, 1989). The post-operative pain is probably related to the sealing of the nerve endings at the time of surgery (Verschueren and Oldhoff, 1982).

The slow rate of healing is a recognized feature of the laser wounds. The results of the healing time in our work- median 5.6 weeks- were comparable to those mentioned in other studies (McBurney and Roson, 1984; Logan and Zachary, 1989). Because of the slow healing of laser wounds, the choice and frequency of dressing may have a significant bearing on the rate of healing and post operative pain. Although the wounds –in this study- were allowed to heal by secondary intention with the mean time of full reepithelization mentioned above. There was a low incidence-6%- of infection. This was probably due to self-sterilizing action of the laser light and the routine use of topical Gentamicin post-operatively.

This study has confirmed the ability of the CO<sub>2</sub> laser to eradicate otherwise resistant cutaneous viral warts. However, critical appraisal of our patient at follow up has demonstrated less than expected results-in spite of all modifications done- as measured by several criteria like cure rate, post-operative pain and scarring. To reduce suffer, it is necessary for laser users to define - more definitely - the

patient groups for whom such treatment is indicated. This will require long-term parallel study comparing laser treatment with other modalities taken into account recurrence rate, complications and cost.

## Conclusion

Carbon dioxide laser therapy of recalcitrant and extensive viral warts should be considered as a viable alternative to other more traditional techniques .This treatment can offers good results in eliminating the verrucae and minimizing the squeals of recurrence, scarring and the post-operative pain.

## References

- Apfelberg D.B., Druker D., Maser M. R., White D. N., Lash H. and Spector P. (1989) *Benefits of the CO<sub>2</sub> laser for verruca resistant to other modalities of treatment*, J. Dermatol. Surg. Oncol. **15**, 371- 5
- Borovoy M., (1987) *The treatment of verrucae vulgaris with carbon dioxide laser surgery*. Clin-Podiatr-Med-Surg. **4**, 799- 807
- Kenton- Smith J. and Tan S. T. (1999) *Pulsed dye laser therapy for viral warts*, British Journal of Plastic Surgery **52**, 554– 8
- Landsman M. J., Mancuso J. E., and Abramow S. P. (1992) *Carbon dioxide laser treatment of pedal verrucae*, Clin-Podiatr-Med-Surg. **9**, 659- 69
- Lauchli S., Kempf W., Dragieva G., Burg G. and Hafner J. (2003) *CO<sub>2</sub> laser treatment of warts in immunosuppressed patients*, *Dermatology* **206**, 148- 52
- Logan R. A. and Zachary C. B. (1989) *Outcome of carbon dioxide laser therapy for persistent cutaneous viral warts*, Br J. Dermatol. **121**, 99- 105
- Markus T., Krell B. and Reinherz R. (1988) *CO<sub>2</sub> laser techniques in destruction of verrucae plantaris: discussion of the blister technique, a more complete method wart ablation*, J. Foot Surg. **27**, 217- 21
- McBurney E. L. and Roson D. A. (1984) *Carbon dioxide laser treatment of verrucae vulgares*, J. Dermatol. Surg. Oncol. **10**, 45- 48
- Savoca S., Nardo L. G., T. F. Rosano T. F., D'Agosta S. and Nardo F. (2001) *CO<sub>2</sub> laser vaporization as primary therapy for human*

- papillomavirus lesions: A prospective observational study*; Acta Obstetrica et Gynecologica Scandinavica **80**, 1121- 4
- Scott R. S. and Castro D. J. (1984) *Treatment of condyloma acuminata with carbon dioxide laser: A prospective study*, Lasers Surg. Med. **4**, 157- 60
- Serour F. and Somekh E. (2003) *Successful treatment of recalcitrant warts in pediatric patients with carbon dioxide laser*, Eur. J. Pediatr. Surg. **13**, 219- 23.
- Sloan K., Haberman H. and Lynde M. (1998) *CW Carbon dioxide laser-treatment of resistant verrucae vulgaris: retrospective analysis*, J. Cutan. Med. Surg. **2**, 142- 5.
- Sterling J. C. S. and Kurtz H. B. (1998) *Viral infection in; champion RH, Burton JL, Burn DA, Breathnach SM*, Textbook of dermatology, 6th ed. Vol. 2, Oxford, Blackwell Science, pp 1029- 45
- Street M. L. and Roenigk R. K. (1991) *Recalcitrant periungual verrucae: the role of carbon dioxide laser vaporization*, J. Am. Acad. Dermatol. **25**, 730- 1.
- Takac S. (2000) *The CO<sub>2</sub> laser and verruca vulgaris*, Med. Pregl. **53**, 389-93
- Verschueren R. C. and Oldhoff J. (1982) *"General Surgery"* in Andrew A. H. and Polanyi T. G. (eds) *Microscopic and endoscopic surgery with the CO<sub>2</sub> laser*, Boston, John Wright PSG Inc. pp 352- 60.
- Williams H. C., Potter A. and Strachan D. (1993) *The descriptive epidemiology of warts in British schoolchildren*, Br. J. Dermatol. **128**, 504- 11.

## طريقة جديدة لمعالجة التآليل الفيروسية بليزر ثنائي أوكسيد الكربون

محسن عبد الحسين الظالمي

قسم الامراض الجلدية , كلية الطب, جامعة الكوفة , الكوفة , العراق

يهدف البحث الى اجراء دراسته لمعالجة التآليل الجلدية بليزر ثنائي اوكسيد الكربون بطريقة منتظمة  
تعتمد على اختيار معلمات الليزر وطريقة العلاج وشروط السلامة بشكل مدروس . انجزت الدراسة في  
قسم طب الامراض الجلدية بمستشفى النجف التعليمي ، حيث تم اختيار اثنان واربعون مريضاً لأنجاز الدراسة ، تمت  
متابعتهم بعد العلاج لفترة ثلاثة شهور . التآليل العنيدة والمنتشرة كانت موضوع الدراسة واستخدم ليزر ثنائي اوكسيد  
الكربون المستمر وبنقطة تعريض 1 ملم لعلاج الحالات المرضية فيما تركت 19 حالة بدون علاج واعتبارها كمجموعة  
ضبط . قسمت الحالات المرضية الى مجموعتين ، ضمت الاولى 60 آفة قسمت ثانياً الى ستة مجاميع متساوية  
عرضت كل منها الى كثافات قدرة ليزر مختلفة ونمطين للتطبيق لدراسة كثافة القدرة المناسبة ونمط التطبيق الأفضل .  
أما المجموعة الثانية والتي تضم 75 آفة فقد عولجت بالليزر وبقدرة 10 واط وبالنمط المستمر وبالطريقة الحزونية .  
اشارت النتائج الى ان افضل قدرة مستخدمة للمجموعة الأولى كانت 10 واط وبالطريقة الحزونية كونها الأسهل عملياً  
. أما في المجموعة الثانية من المرضى فبعد تعرضهم الى اشعة الليزر 1 - 6 مرات (بمعدل 2ر8) تبين ان هنالك  
زوال كامل للآفات فيما لم يتم ملاحظة زوال أية آفة من تلك التي تركت بدون علاج . يمكن الاستنتاج بأن المعالجة  
بليزر ثنائي اوكسيد الكربون المستمر للتآليل الفيروسية العنيدة والمنتشرة يعتبر بديلاً ناجحاً للتقنيات التقليدية الأخرى  
حيث اظهرت النتائج ازالة التآليل بشكل كامل دون ترك ندب او ألم بعد العملية .

