



Clinical Observation and Performance of High Power Diode Laser in the Treatment of Oral Lesions

Maral I. Seeron⁽¹⁾ Ayad M. Ismail⁽²⁾ and Khalil I. Hajim⁽³⁾

(1) Al-Wasity Hospital for Reconstruction Surgery, Baghdad, Iraq

(2) Hospital of Generalized Surgery, Baghdad, Iraq

(3) Institute of Laser for Postgraduate Studies, University of Baghdad, Iraq

(Received 16 February 2005; accepted 12 October 2005)

Abstract: In this work, oral lesions belong to 17 patients, 7 males and 10 females. Their ages range between 15 and 45 years. Follow up was conducted after one day, 7 days, 14 days, one month, and finally 3 months postoperatively. The study lasted for 1.5 year. Surgical diode laser with wavelength of 810 ± 20 nm, with two power levels of 10 and 15 W were used in contact and in non-contact mode via optical fiber. The postoperative outcome revealed; greater haemostatic capability, dry, sealed wound and noticeable lack in pain sensation

Introduction

The twentieth century introduced many improvements and developments in the quality of various materials and processes used in dentistry by the invention of laser (Stookey, 1998; Pick and Powell, 1993). Performance of high power diode laser with different laser dose parameters and applicator modes via clinical observations in the use of this laser in the management of different oral lesions during the operation time and follow up appointments of the operated on side were the aim of this study.

Diode lasers emit light in the range of near infrared region to the visible red region. The main advantages of semiconductor laser are its compactness, simplicity and efficiency. They require very little auxiliary equipment and can be readily linked to optical fibers that enable the diode laser to be used for medical purposes (Tarasov, 1983; Senior, 1985).

The oral lesions were divided into five groups according to the type of the lesions, these groups were; Pyogenic granuloma group, Gingival fibromatosis group, Sturge-Weber Syndrome group, Erosive lichen planus group, and Implant group that subdivided into (A)-Stage II-at time of recovery and (B)-Soft tissue removal group as displayed in Table (1). The conventional

treatment of pyogenic granuloma is by surgical excision using scalpel, after that curetting away any remaining fragments at the base and root planning was undertaken.

The resultant wound is dressed with a periodontal pack (Shafer et al., 1983), the underlying irritant factors should be corrected (Seward et al, 1987), and otherwise the lesion tends to reoccur (Bhaskar, 1980).

Table 1: Classification of the lesions into groups.

LESION GROUP	PATIENTS NO.	LESIONS NO.
Pyogenic Granuloma group	4	4
Gingival Fibromatosis group	1	8
Sturge-Weber Syndrome group	1	2
Erosive Lichen Planus group	1	1
Implant group		
A. Stage II-at Time of recovery	7	7
B. Soft tissue removal group	3	3

For Gingival fibromatosis the surgical treatment is by gingivectomy to remove the excess fibrous tissue by surgical knife, then periodontal-pack was used to cover the inflamed gingival and prevent re-infection during healing. The pack replaced daily or every other day, but may be left for longer time, the period of treatment may be 2 or 3 weeks. Sturge-Weber Syndrome group treatment is by excision of mucosal enlargement and hemangiomas areas then pressure pack or anticonvulsant drugs may be used to control the repeated episodes of bleeding (Wood and Goaz, 1997). Cryosurgery may also be used for the removal of a haemangioma (Cawson and Odell, 1988). There is no specific treatment for lichen planus, corticosteroid therapy has been used to relieve the inflammation (Shafer et al., 1983), like the application of steroid creams such as kenalog in orabase (Wood and Goaz, 1997) or by intra lesion injections of corticosteroids (Carranza 1979; Geoffrey et al., 1985). For Implant Group after 6 months from implant placement and osseous integration completed, the excess tissues over implant were removed to expose the cover screws. A scalpel is used to make an incision and raise a flap. Repositioning the edges of the flap, and press them against the underlying bone then suturing is made along the entire incision line. Sometimes additional removals of gingival tissue is required by removing and trimming the gingiva, by gingivectomy and then wound covered with periodontal -pack for 2-3 weeks to complete the healing (Weiss, 2001).

Materials and Methods

The Diomed surgical laser system was used in this project, which is a surgical diode laser incorporates class IV GaAlAs, with a wavelength in the range of 790 - 830 nm, and a treatment mode of continuous, pulsed, repeated pulse, with a pulse duration that ranges from 0.1 to 1 s, and pulse interval that ranges from 0.1 to 1 s, delivering 15 W of continuous wave laser radiation. The laser energy was delivered to the treatment site by means of a flexible optical fiber coupled to the laser aperture. This laser has a visible aiming beam of 4 mW power with a wavelength in the range of 635-660 nm at laser aperture.

Without any premeditations and sedative treatment, all the patients were anesthetized during the surgical operation by local infiltration of Anesthesia; containing Adrenalin at

concentration of 1:80000. After giving anesthesia, diode laser with optical fiber delivery system was introduced in contact mode with the tip of the fiber perpendicular on the tissue in slow motion. With laser power of 15 W, pulse interval of 0.1 s, 0.3 s, and pulse duration of 0.3 s, 0.1 s, respectively. Again, diode Laser in contact mode, with 10 W laser power, pulse interval of 0.1 s, 0.3 s, and pulse duration of 0.3 s, 0.1 s, respectively, were used to excise the remaining of the lesion. Both these parameters are displayed in Table (2).

Table 2: Laser dose parameters applied to the patients in each group with different oral lesions in both contact and non contact mode.

Power (W)	Pulse interval (s)	Pulse duration (s)
15	0.1	0.3
15	0.3	0.1
10	0.1	0.3
10	0.1	0.3

The carbonization layer that was formed during application of the laser dose parameters was wiped away to permit visualization and to judge whether further exposing was necessary. In non-contact mode different laser parameters were used, with laser power of 15W, pulse interval of 0.3 s, 0.1 s, and pulse duration of 0.1 s, 0.3 s, respectively, as summarized in Table 2. The wound was lased in criss-cross pattern for generalized haemostatic effect.

After each operation, the patient was instructed for normal brushing as well as chlorhexidine mouth wash in concentration of 0.2%, once a day. Moreover, the black carbonized layer, which appears at the surgical side not to be removed. All the patients were given an appointment for follow-up.

Results and Discussion

The results based on the inspection of the wound side following a day after operation, one week, fourteen days, one month and finally, after three months postoperatively. Inspection included observation of any bleeding, edema,

infection, ulceration, bone exposure, scar formation, and necrosis of the operation site. Moreover, the patients complaint during the follow-up appointments. All the surgical operations were done without the use of any suturing or surgical packs. After analyzing the results, conclusions were made. The result of the operation was the same in all groups that operated by diode surgical laser. The follow-up result was as follows: During operation, the patients showed no complain there was no pain or bleeding following the operation. One day following the operation the intra-oral examination showed dark-brown necrotic tissue, friable, with red inflamed line around the edges, no bleeding was seen from the laser wound as shown in Fig. (1-A), also in Fig. (2-A) for implant group revealed the same results, which was no bleeding and no need for suturing following the operation. So the laser allows for

the immediate impression taking, at the same appointment Fig. (2-B). Extra-orally there was a mild edema, swelling at the operated side. After five days, the observation revealed that the carbonize layer was completely changed to white slough tissue and was easily removed by gauze, there was no infection, and no ulceration or bone exposure as shown in Fig. (1-B). After two weeks, the inspection of the operated site showed complete healing, with no slough tissues, no ulceration. There was soft friable granulation tissue covering the radiated area, as shown in Fig. (1-C). One month from operation, the tissue appearance had improved with complete healing. There were no sign of any infection or ulceration. Three months post-operatively, the gingiva looked normal in color, dense, firm in nature. There was no evidence of any abnormality in the operated area.

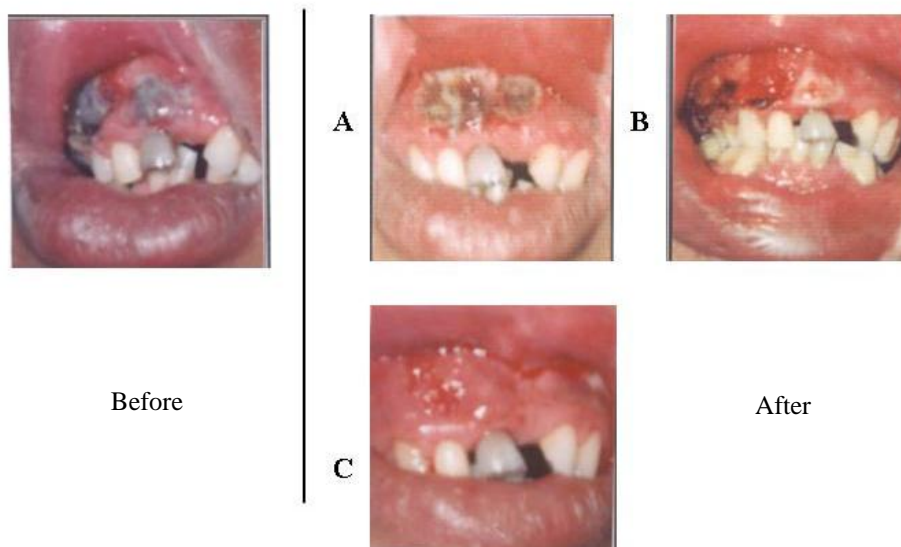


Fig. 1: A. Sturge-Weber Syndrome at the upper anterior segment of the gum immediately after the operation, B. five days postoperatively, C. fourteen days after the operation.

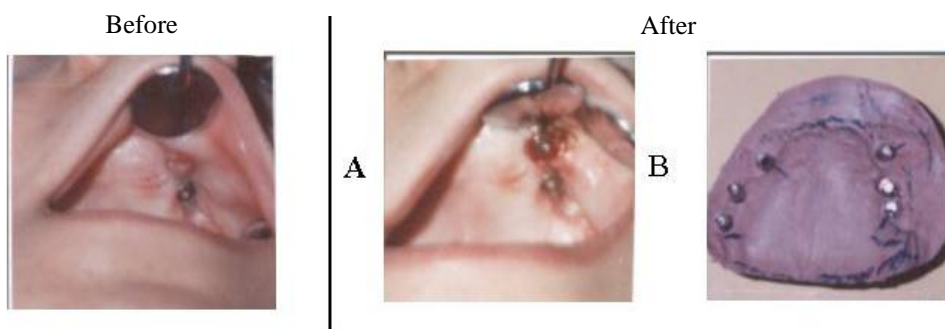


Fig. 2: Granulation tissues over the implant before exposure of implant fixture for placement of gingival former. A. immediately after operation, there was noticeable lack of bleeding. B. Cast molding after impression taking in the same operated day.

Photothermal interaction with tissue is the basic concept of 810 nm diode surgical laser. In this process, thermal effects have their origin in bulk absorption occurring in molecular vibration-rotation bands followed by non-radiation decay, transferring the photon energy to kinetic energy to the surrounding molecules (Markolf, 1996). This in turn is a form of heat energy changing tissue structure (Neckel, 2001). Laser light within 810 nm is converted to thermal energy on contact with the tissue, causing laser tissue interaction, that when appropriately applied, can produce reaction ranging from incision, vaporization, to coagulation (Clayman, 1997; Pratesi and Sacchi, 1980). This wavelength has affinity for melanin or dark pigments, and is strongly absorbed by the blood hemoglobin, which contributes to their thermal effect (Neckel 2001; Dierickx et al., 2002; Featherstone, 2000). This was the reason that haemeostasis occurs with this wavelength through the heating of elements, and by direct sealing of small blood vessels, by desiccation and contraction of the vessel wall (Grossman et al., 1997).

In comparison between the two laser dose parameters in the contact mode application, in both 10 W and 15 W group, with different pulse intervals and pulse durations, it was obvious that, with 10 W power setting with its different parameters, the exposed area was again vaporized and coagulated in the same manner as in the case of the 15 W laser parameters. Nevertheless, but there was a delay in the time of operation, and with less penetration depth in comparison to the 15 W parameters. Also a laser pulse with a duration of 0.3 s and a shorter pulse interval of 0.1 s, cause more penetration than a shorter pulse duration of 0.1 s and a longer pulse interval of 0.3 s. The reason for that was related to the fact that in the pulse duration of 0.3 s, and pulse interval of 0.1 second, the energy is deposited with less thermal relaxation time and therefore, has a more penetration depth that was directly proportional to the total time of exposure. Conversely, a pulse duration of 0.1 s and a longer pulse interval that was equal to 0.3s, the longer intervals between pulses (lower pulse repetition rate) will generate less heat with oral soft tissue (Miserendino and Pick, 1995).

Changing from contact mode to non-contact mode will create larger spot size and will result in a lower power density across the area of the beam, thus causing the superficial layer to be vaporized (Miserendino and Pick, 1995; Kao and Hockham, 1966). Therefore, deeper penet-

ration was avoided by sweeping the beam over target tissue while defocusing it to achieve a coagulation zone of 1-3 mm by using 10 and 15W parameters (Dedrich, 1993). For a non-contact mode, 15 W laser dose parameters allowed good haemostatic and vaporization effect, through the heating of elements, and by direct sealing of small blood vessels, by desiccation and contraction of the vessel wall. It displayed greater haemostatic capability. It was clear that non-contact surgery reduces the potential of contamination of the wound in addition to the thermal destruction of bacteria that explained the lack of infection (Clayman, 1997; Featherstone et al., 2000).

During vaporization of lesions, charring layer developed and starts to simultaneously exhibit a deeper concentric thermal damage zone, the carbonized layer starts impeding the radiation and thus, hampers the heating of the rest of the surrounding tissue (Gelfond et al., 2000; Wood, 1997). This layer was removed with wet gauze during surgery, so the lesion can be visualized to know if further vaporization of the lesion is required (Catone and Alling, 1997; Berger, 1999). This process of lasing and wipe down can be continued until normal tissue is exposed.

Conclusions

Lack of infection during healing periods due to the final char layer that was applied act as a bandage and permit a traumatic healing. That offers protection during healing. This work findings emphasize that the ability of laser to perform haemostatic surgery by sealing blood vessels; result in a clean, dry, and sealed wound (Grossman et al., 1997). The ability of diode laser to seal the lymphatic vessels at the time of surgery is another advantage in decreasing the swelling and edema associated with the surgery (Kenyon, 1997). In addition, the possibility of cauterizing and sealing the neural pathways apply advantageous in reducing postoperative discomfort, such as pain sensation, which is in consistent with other finding.

References

- Bhaskar S.N., (1980) *Orban's Oral Histology and Embryology*. C.V. Mosby Co., 9th Ed. p.283, 284, pp. 288-310.

- Carranza F.A., (1979) Clinical Periodontology. W. B. Saunders Co., 5th Edt., pp. 3-6, p. 157, 307, 533.
- Catone G. A., Alling C. C. (1997) Laser Application in Oral and Maxillofacial Surgery. Philadelphia, W. B. Saunders Co., pp. 30-40, 115-146, 181-193.
- Cawson R.A., Odell E.W. (1988) Essentials of Oral Pathology and Oral Medicine, 6th Edt., Harcourt Brace & Co, p. 44,156, pp. 200-220
- Clayman L. (1997) Oral and Maxillofacial Surgery Clinics of North America. W.B. Saunder, Vol. 9, pp. 8-17, 33-42.
- Dedrich D.N. (1993) *Laser-Tissue Interaction*. J. Am. Dent. Ass. pp. 57-61
- Dierickx C.C., Anderson R. R., Campos V. B., Grossman M.C. (2002) *Effective, Permanent Hair Reduction Using a Pulsed, High-Power Diode Laser*. Wellman Labs of Photomedicine, Harvard Med. School, and Laser and Skin Surgery Centre of New York, Coherent Medical, Inc.
- Featherstone J.D., Rechman P., Fried D. (2000) *Laser Assisted Treatment of Patient with Hemorrhagic Disorder*, Laser in Dentistry 1, No. 4, San Jose, CA, pp. 20-22
- Gelfond M.L., Mizgirev I.V., Barchuk A.S. et al. (2000) *Selective Laser Hyperthermia of Malignant Neoplasms: Experimental and clinical research*. Petrov Res. Inst. of Oncology, Med. Acad. for Postgraduate Educ., ATC-semiconductor devices.
- Howe G.L., Bastion R.J., Wilkinson F.C. (1985) *Minor Oral Surgery*, John Wright and Sons, 3rd Ed. pp. 1-20
- Grossman M.C., Kauvar A.N., Geronemus R.G. (1997) *Cutaneous Laser Surgery*. Lippincott-Ravan Pub., pp. 321-350
- Kao K.C., Hockham G.A. (1966) *Dielectric-fiber surface waveguide for optical frequencies*. Proc. IEE 133, 1151-1158
- Kenyon G.S. (1997) *Diode Laser Nasal Surgery*, Diomed Ltd, Cambridge
- Miserendino L.J., Pick M. (1995) *Laser in Dentistry*, Quintessence Pub. pp. 35-54, 114-120
- Neckel C. (2001) *Comparative study on CW mode versus pulsed mode in GaAlAs diode laser*. From www.Cpneckel@t-online.de
- Pick R.M., Powell G.L. (1993) *Laser in Dentistry: Soft-Tissue Procedures*. Vol. 37, No. 2. April, pp. 288-295
- Pratesi R., Sacchi C.A. (1980) *Laser Photomedicine and Photobiology*, Springer-Verlag, Berlin
- Senior J.M. (1985) *Optical Fiber Communications: Principles and Practice*. Prentice Hall Int., London. pp. 11-17, 232, 262-263
- Seward G.R., Harris M., MCGowan D. (1987) *Killey and Kay's Outline of Oral Surgery, Part 1*. IOP Pub. Ltd, Bristol, 2nd Ed. pp. 1-7
- Shafer W.G., Hine M. k., Levy B.M., Tomich C.E. (1983) *A Textbook of Oral Pathology*, Saunders Co., 4th Ed. p. 158, 359, 785, 810
- Stookey G. (1998) *Early Detection of Dental Caries: Quantitative Laser Fluorescence*, Indiana University, Research and Creative Activity, Vol. XXI No. 2
- Tarasov L.V. (1983) *Laser Physics*, translated from Russian by R.S. Wadhwa, MIR Pub., Moscow, p. 13, pp. 81-89
- Weiss C.M. (2001) *Principles and Practice of Implant Dentistry*, Mosby, Inc. pp. 131-140
- Wood N. K., Goaz P. W. (1997) *Differential Diagnosis of Oral and Maxillofacial Lesions*, Mosby, 5th Ed. p. 21, 40, pp.151-157, 300-305

الملاحظة السريرية وأداء ليزر الدايدود عالي القدرة في معالجة جروح الفم

مارال أيشخيان سيرون⁽¹⁾ أياد محمد أسماعيل⁽²⁾ خليل أبراهيم حاجم⁽³⁾

(1) مستشفى الواسطي للجراحة التقيومية ، بغداد ، العراق

(2) مستشفى الجراحة التخصصية ، بغداد ، العراق

(2) معهد الليزر للدراسات العليا ، جامعة بغداد ، بغداد ، العراق

الخلاصة
تعود جروح الفم إلى 17 مريضاً ، بينهم 7 ذكور و 10 إناث تراوحت أعمارهم بين 15 و 45 سنة . أجريت المتابعة بعد يوم واحد ، 7 أيام ، 14 يوماً ، شهر واحد وأخيراً 3 شهور بعد الجراحة . الدراسة دامت لمدة سنة ونصف واستخدم ليزر الدايدود الجراحي بطول موجة 810 نانومتر وبقدرة 10 و 15 واط بصورتين ، مباشرة ، وغير مباشرة باستخدام الليف الضوئي . أظهرت النتيجة ما بعد الجراحة قابلية أكبر للـ **haemostatic** وجفافاً وألتاماً سريعاً للجرح وإحساساً أقل بالألم .