



## Diagnosis and Treatment of Cervical Intraepithelial Neoplasia with Carbon Dioxide Laser Therapy in Selected Patients

Intisar. H. Al-Tawjery <sup>(1)</sup> Hussein. A. Jawad <sup>(2)</sup> and Balsam. M. Mirdan <sup>(2)</sup>

(1) Al-Alwayia Maternity Teaching Hospital, Baghdad, Iraq

(2) Institute of Laser for Postgraduate Studies, University of Baghdad, Baghdad, Iraq

(Received 6 September 2009; accepted 5 January 2010)

**Abstract: Background** Female infection with HPV (human papilla virus) has been established as an essential cause of CIN (cervical intraepithelial neoplasia). The danger of transformation from CIN to frank malignancy should be considered. **Objective:** The goal of this study is to evaluate the effectiveness of CO<sub>2</sub> laser vaporization of ectocervical lesion high grade squamous intraepithelial lesion (HGSIL). **Patients and Methods:** Four Female out of 150 affected with HGSIL lesions were submitted to CO<sub>2</sub> laser vaporization and followed up in 4 months later, and 10 women with HGSIL lesion submitted to electrocautery diathermy for the comparison. **Results:** Among women treated by CO<sub>2</sub> laser vaporization, 3 women had negative results (clear cervix), at 4 months follow up; one woman had recurrence at 4 months following up, the recurrence was due to incomplete destruction of the deepest part of the lesion involving the glandular crypts. **Conclusion:** The preservation of the anatomical integrity of the cervical tissue offers a better follow-up of those patients. Although other treatment modalities are available, CO<sub>2</sub> laser represents an acceptable surgical tool for the management of cervical intraepithelial neoplasia (CIN) with minimal complications.

**Keywords:** CIN-cervical intraepithelial neoplasia-CO<sub>2</sub> carbon dioxide laser –HGSIL high grade squamous intraepithelial lesion. LGSIL low grade intraepithelial lesion, SCJ squamous columnar junction.

### Introduction

Human papilla virus (HPV) has been established as an essential cause of (cervical intraepithelial neoplasia) CIN. HPV is a double –stranded DNA virus of the papovaviridae family. High –risk HPV types (16,18,31 and 45) exhibit the strongest association with cervical malignancy [Munoz N et al].The major steps of cervical carcinogenesis include HPV infection, viral persistence and progression to precancerous and invasion. The risk factors include viral load or infection with multiple HPV types. HPV infection in individual genetic is predisposition to malignancy, in addition to the environmental factors, cigarette smoking

[Ho, G et al], contraception [Moreno V et al], HIV [Ho, G et al] infection and other sexually transmitted infection like herpes, Chlamydia, syphilis or trichomons.

The peak age incidence of HPV infection is in the age band of 20-24 years then declines gradually to about the age of 40-45 years and then begins to increase slowly. The outcome of laser therapy on fertility, during follow-up period, is as follows:

One woman following laser vaporization (6 months later) got pregnant, so the ablative laser therapy had negative impact on fertility [Montz FJ]. There was no relationship found between laser vaporization and pregnancy outcome and delivery [Van Rooijen M and Persson E].

Ablative laser therapy had less effect on cervical stenosis than excision therapy [Diakomanolis E et al].

The excision therapy with or without laser is associated with significantly increased risk of premature rupture of membrane and premature delivery, but not with laser vaporization [Sadler L et al]. Any surgical procedure on the uterine cervix especially recurrent procedures or the destruction of a large volume of cervical tissue is associated with a loss of cervical volume and may result in an incompetent cervix or premature labor [Spitzer M].

### **Materials and Methods**

The study was done at AL-Nu'man Hospital, department of Obstetric and Gynecology, during the period from August 2003 to July 2004, a total of 150 women had already undergone screening with Pap smear.

Every woman received a request form involving patient's name, age, last menstrual period, menstrual history, previous Pap smears, marital status, duration of marriage(at least 2 years), number of children, contraceptive pill, smoking and number of marriage(multiple sexual partner).

The age band selected in this study was between 18-55 years. Samples prepared as follow:

-Lab studies-this includes cytology that means Pap smear.

-Colposcopic examination and colposcopy directed biopsy for histopathology, when Pap smear shows abnormal epithelium.

The criteria to be fulfilled prior to laser vaporization includes:

-The CIN must occupy the ectocervix with no extension into the endocervical canal.

-A correlation must exist between cytology, colposcopy, and histology.

-The diagnosis of micro invasive and invasive cancer should be eliminated.

The geometry of ectocervical CIN is central, cylindrical dome-shaped defect, which incorporates both the ectocervical linear length and the underlying crypt involvement height at least 5 mm along the entire lesion.

The dose parameters for CO<sub>2</sub> laser used in this work are

-Power 25-30W (mainly 25W used)

-Power density 1k-2kW/cm<sup>2</sup>

-Spot size 1.5-2 mm (1.5 mm used)

-Exposure time 0.1sec (CW mode [chopped laser])

-Speed of treatment 1 cm/sec

-Operation time 10-20 minute

The above doses were used for vaporization of cervical dysplasia with minimal thermal damage to adjacent areas. The same laser setting may be used to coagulate by enlarging the spot size or by reducing the power setting on the laser.

The squamose columnar junction (SCJ) is identified by colposcopic examination marked the SCJ with laser beam at anterior 12 o'clock, the posterior 6 o'clock and both lateral sides 3 and 9 o'clock, connecting the 4 spots to make a circle that surrounds the area to be vaporized, the cervical lesion is surrounded by a margin of 3 mm of normal appearing cervical tissue. Next, the cervix was divided into 4 quadrants, vaporization was done in each quadrant and then move to the next. The joystick was moved in vertical, horizontal, and diagonal lines. The depth to be reached was not more than 7mm, reaching the desired depth by periodic measurement using micro ruler or by noticing the mucus bubbling up from the base of the lesion.

The out put power used in first woman was 25 W and depth of 5 mm (as a beginning we used a micro ruler to measure depth). The laser was operating in a CW mode; the chopping (exposure) time was 0.1 sec. Failure rate was encountered 4 months later on first Pap smear, because not all the involved crypts of glands were vaporized. For the other three women we used the power of 25 W, CW modes, and to a depth of 7 mm (depending on mucus bubbling). Four months later Pap smears were negative, so we reached to the desired depth. The time of exposure was fixed 0.1 sec to get less heat dissipation to the surrounding tissue to prevent the occurrence of cervical stenosis which followed prolonged exposure time and low power density [Wryght VC and Riopell MA].The time of operation was varied, at the first time we spent 20 minute, it was a bit long, but later, the time was 10 minutes. As the power density of the beam was increased the beam was moved faster over the tissue to control depth. This caused less and less thermal transfer around the zone of vaporization. The reasons behind selection of cases with CIN-2 are affecting the ecto cervix. This procedure was easily performed while led to a low recurrence rate compared with cases affecting the

endocervix, the SCJ was not well visualized during therapy and had high recurrence rate and may need repeated procedure which may cause damage to cervical tissue in addition to other possible encountered complication. The advantage of laser vaporization of ectocervix is, that the SCJ will be visible in 90% to 95% of women and the incidence of cervical stenosis is low.

### Results

A total of 150 women have been screened with Pap smear. According to Bethesda , 92 women out of 150 were grouped into 3 groups as follow:

**Group 1** consisted of 50 cases most of them with inflammation ASC-US.

**Group 2** consisted of 24 cases of LGSIL (CIN1).

**Group 3** consisted of 18 cases with HGSIL (CIN2).

The patient group is listed in Table (1)

**Table (1):** Groups of patients according to Bethesda system

SIL GRADE	No	%
ASC-US	50	54.3
LGSIL	24	26.1
HGSIL	18	19.6
TOTAL	92	100.0

From table (1) the ASCUS cases are inflammation that doesn't need laser therapy. The LGSIL cases had risk of 21% of progression into invasion, this also left without treatment only follow-up. HGSIL cases were our concern in this study

The average ages of ASC-US is 25 years, while for LGSIL is 30 years, and HGSIL is 35 years as shown in Table (2):

**Table (2):** The average age of affection with cervical dysplasia.

SIL GRADE	Mean ± SD (yrs)
ASC-US	25
LGSIL	30
HGSIL	35
ALL GRADES	30

From the above results women aged above 30 years affected with HGSIL. The women with LGSIL about 24 of the patients were left without treatment only for follow-up with Pap smear every 4 months. The other three negative results of the patients were shifted to annual follow-up.

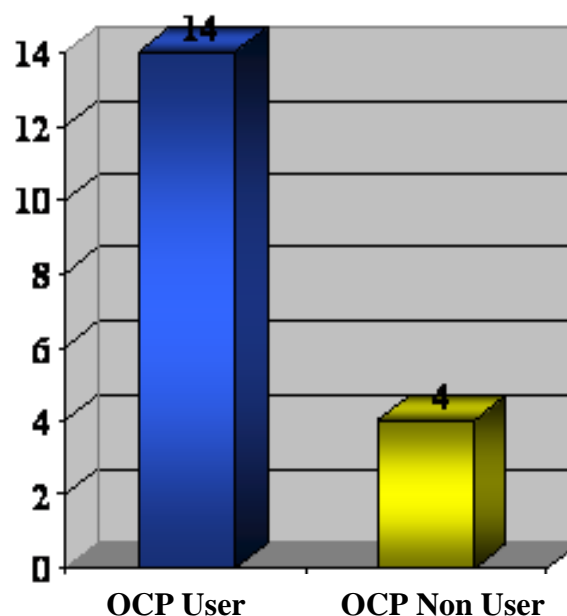
After correlation between cytology and histopathology for 18 cases, four women who were not willing to get pregnancy anymore were subjected to total abdominal hysterectomy and bilateral salpingoopherectomy.

Out of four women submitted to laser therapy by CO2 laser as out patient procedure, with follow –up after 4 months, one woman showed recurrence. Women were treated by laser they were scheduled in follow-up program.

The other 10 women with HGSIL were submitted to electrocautery diathermy (conventional's method).

According to risk factors (oral contraceptive pills, multiple partner, and high parity) results of data for HGSIL are presented as follows:

Figure 1. shows that there is strong relationship of HGSIL with oral contraceptive user women



**Fig.(1):** Risk of HGSIL infection in relation to o.c.p user and non-user

Also the women with high parity more than 4 had high risk of infection with HGSIL as shown in Figure 2.

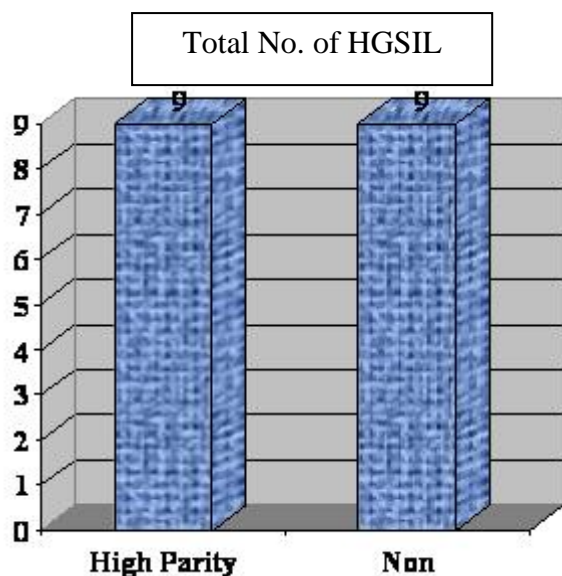


Fig. (2): Risk of HGSIL infection in relation to high parity

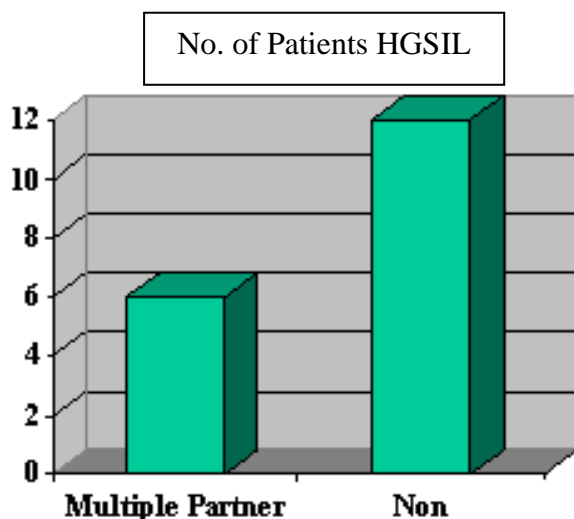


Fig. (3): Risk of HGSIL infection in relation to multiple partner (2nd marriage)

No report of infection or bleeding in treated cases of HGSIL with laser were observed as shown in Table (3).

Table (3): The complications among LASER treated versus electrocautery cases.

Complications	No. of electrocautery cases (n=10)	%	No. of laser cases (n=4)	%
Bleeding	5	50	0	0
Infections	1	10	0	0
Total	6	60	0	0

## Discussion

The goal of treating cervical dysplasia is to eliminate the abnormal cells before they have a chance to progress to invasive carcinoma [Fallani MG et al]. A variety of treatment of cervical dysplasia exists, ablation or excision. Our concern is about ablative treatment that includes vaporization by laser and electrocautery diathermy. This study is to enable us to assess the effectiveness of laser in treating cervical dysplasia and compare females who had HGSIL treated with laser from other females also with HGSIL treated by conventional method electrocautery diathermy.

Selection of CO<sub>2</sub> laser for this procedure depended on absorption of its energy by water content of the cervical tissue and consequently produces heat which is sufficient to vaporize the tissue.

Previous study by Lisowski P, Knapp in 1999[Lisowski P et al], women aged 18-46 were treated either by LIETZ or CO<sub>2</sub> vaporization, final results were evaluated from 6 month to 4 years after the treatment. The effectiveness of CO<sub>2</sub> laser vaporization was 94.9% and was similar to LIETZ 96.4%. Ablative laser therapy is effective and competes with other ablative and excision therapy.

In this study although the samples were relatively small, the results obtained were adequate enough to visualize the effect of using CO<sub>2</sub> laser in treating women with cervical dysplasia.

For 18 women with HGSIL 14 were oral contraceptive user) 77.8%, 9 were multipara: 4 child, 33.8% they had second marriage experience.

The visibility of the SCJ in laser vaporization of electro cervix was 90% to 95% and the incidence of cervical stenosis was low.

It is important to note that women that were submitted to laser therapy a 10mg of diazepam was enough as a sedative, i.e. there was no need to use general anesthesia (G.A.).

For the conventional treatment cases the outcome from 10 women were subjected to electrocautery diathermy to a depth of 7mm, under G.A. was five women got bleeding intra-operative which was controlled by packing the vagina.

The post operative pain in patient that were subjected to electrocautery was more in comparison with patients who had received laser treatment. It was controlled by post operative

sedation and long hospital stay for 24 hours post operatively, in contrast to laser therapy patients only one hour stay was enough including the time of procedure.

The follow-up protocol was done by cytology test and periodic colposcopy every 4 months. After 3 negative pap smear results the patients were shifted to annual follow-up.

The previously mentioned chosen laser parameters to vaporize CIN-2 in the ecto cervix was safe with no apparent damage to the cervix, no recurrence was recorded in pap smear follow-up. The parameters were reproducible and the depth of the vaporization which was reached via laser therapy was optimum to get high cure rate in contrast with the first women where neither the laser out put power nor the vaporization depth was enough to gain the cure.

The recurrence was recorded after 4 month follow up for this patient.

### Conclusion

The preservation of the anatomical integrity of the cervical tissue offers a better follow-up of those patients. Although other treatment modalities are available, CO2 laser represents a successful surgical tool for the management of cervical intraepithelial neoplasia (CIN) with minimal complications.

### Acknowledgment

Many thanks to Dr. Nada. S. Ameen Department of Gyn. and Obst. Medical collage Al-Mustansirya University for her help in preparing the manuscript

### References

Diakomanolis E, Haidopoulos D, Roddakis A, Messaris E, Sakellaropoulos G, Colpoktsoglou C Michalas S. Treating intraepithelial lesions of the uterine cervix by laser CO2, Evaluation of the past, appraisal

for the future. Eur J Gyn Oncol.2002; **23**(5):463-6{Medline}.

Fallani MG, Penna C, Fambrini M, Marchionni M. Laser CO2 vaporization for high –grade cervical intraepithelial neoplasia: a long term follow-up series Gyne Oncol. 2003 Oct; **91** (1): 130-3{Medline}.

Ho GY, Kadish AS, Burk RD, Basu J, Palan PR, Mikhail M and Romney SL, HPV 16 and cigarette smoking as risk factors for high-grade Cancer, International J of Cancer 1998.29;78(3)281-285.

Ho,GY., Burk RB., Fleming I. and Klein RS., A risk of genital HPV infection in women with HIV-Induced immunosuppressant. International J of Cancer; 1994. **56**:785-792.

Lisowski P, Knapp P, Zhroch T, Kobyle CM, and Knapp P. The effectiveness of conservative treatment of cervical lesion using the LLETZ and CO2 laser,Przegl Lek 1999; **56**(1): 72-75.(Article in polish)

Moreno V, Bosch FX, Muñoz N, Meijer CJ, Shah KV, Walboomers JM, Herrero R, and Franceschi S, Effect of oral contraceptive on risk of cervical cancer in women with HPV infection the IARC multicentric case – control study Lancet 2002:359:1085-1092.

Munoz N, Bosch FX, de Sanjose S, Herrero R, Castellsague X, Shah K, Snijders P and Meijer C, Epidemiologic classification of HPV types associated with cervical cancer ,N Engl. J Med 2003,**348**:518-527.

Sadler L, Saftlas A, Wang W, Exeter M, Whittaker J, Mc Cowan III-Treatment for cervical intraepithelial neoplasia and risk of preterm delivery. JAMA 2004 May 5:291(17):2100-6.

Spitzer M: Fertility and pregnancy outcome after treatment of cervical intraepithelial neoplasia .J Lower genital tract disease.1998; 2: 225-30.

Van Rooijen M, Persson E .Pregnancy outcome after laser vaporization of cervix, Acta Obstet. Gyne Scand.1999, Apr; **78**(4):346-8.

Wryght VC, Riopell MA: Gynecology laser surgery a practical Handbook, Houston. Biomedical Communication 1982.

## التشخيص والعلاج للتغيرات الخلوية في خلايا عنق الرحم باستخدام ليزر ثاني اوكسيد الكربون 10600 نانوميتر في حالات منتخبة

انتصار حسن التوجيهي<sup>(1)</sup> حسين علي جواد<sup>(2)</sup> بلسم محمد مردان<sup>(2)</sup>

(1) مستشفى العلوية التخصصي للأمراض النسائية, بغداد ، العراق

(2) معهد الليزر للدراسات العليا ، جامعة بغداد ، بغداد ، العراق

**الخلاصة**  
ان الهدف الرئيسي من هذه الدراسة هي اثبات وتقييم الكفاءة العلاجية باستعمال ليزر ثاني اوكسيد الكربون وذلك بختيار خلايا عنق الرحم الخارجية ذات التغيرات الخلوية. **طريقة الدراسة** : تم اختيار اربعة نساء لديهم تغيرات خلوية في خلايا عنق الرحم الخارجية من الدرجة الثانية وقد تم اخضاعهم للعلاج بليزر ثاني اوكسيد الكربون. تمت متابعة النساء بعد جلسة العلاج بمدة اربعة اشهر بواسطة اجراء فحص خلوي اخر لخلايا عنق الرحم. هذا من ناحية ومن الناحية الاخرى تم اخضاع عشرة نساء لديهم ايضا تغيرات خلوية من الدرجة الثانية الى علاج الكوي الكهربائي التقليدي تحت التخدير العام لمتابعة العمق العلاجي والمضاعفات التي تحصل في كل من الطريقتين العلاجية. **النتائج** : من خلال العلاج والمتابعة وجدنا هناك ثلاثة نساء استفادوا من علاج الليزر وواحدة فشل علاج الليزر معها وذلك بسبب عدم الوصول الى العمق العلاجي الاساسي. **الاستنتاج** : ان استعمال طريقة التبخير في علاج التغيرات الخلوية لخلايا عنق الرحم الخارجي تفيد في ابقاء التشريح الوظيفي لانسجة عنق الرحم بدون تغيرات . ليزر ثاني اوكسيد الكربون يعتبر من الادوات المهمة التي تفيد في علاج هذه الحالة المرضية باقل مضاعفات جانبية جنبا الى جنب ويتنافس مع بقية انواع العلاج الاخرى.