



## Comparative Histological Study of Dentinopulpal Responses in Class I Cavity Treated by Er: YAG Laser and Conventional Cavity Preparations: An in Vivo Trial

Maha W. Al-Gazali<sup>(1)</sup> Ali S. Mahmood<sup>(2)</sup> Lehadh M. Al-Azzawi<sup>(2)</sup> and Rayid K. Jarjess<sup>(3)</sup>

(1) *Rusafa Specialized Medical Center, Ministry of Health, Baghdad, Iraq*

(2) *Institute of Laser for Postgraduate Studies, University of Baghdad, Baghdad, Iraq*

(3) *Alwiya Specialized Center for Dentistry, Ministry of Health, Baghdad, Iraq*

(Received 15 February 2010; accepted 19 June 2010)

**Abstract:** The purpose of this study is to investigate the histopathological response of dentinopulpal response of human teeth to the Er: YAG laser cavity preparation in comparison with the conventional class I cavity preparation. Thirty five sound human upper and lower first premolar teeth which were needed to be extracted for orthodontic purposes were used in the study. Regarding to the method of cavity preparation, the teeth were grouped into three groups; Group1; Control group which consists of seven sound teeth without cavity preparation, Group2; Conventional cavity preparation group and group 3; Er: YAG laser cavity preparation group. Each of Group2 and3 consists of fourteen teeth that is subdivided into: A. 7teeth that extracted after two days after cavity preparation and B. 7 teeth that extracted after twenty-one days after cavity preparation. Er: YAG Laser device emits radiation at wavelength of 2940 nm in the infrared region. The laser irradiation was performed in a non-contact mode with a focused beam of (energy density of 155985.96 mJ /cm<sup>2</sup>, energy of 600 mJ and a PRRs of 6 Hz for enamel preparation) and (energy density=64994.151 mJ /cm<sup>2</sup>, energy = 250 mJ and a PRRs=4 Hz for dentin preparation) with a spot diameter of 0.7mm at 12-15 mm distance and at right angle to the tooth surface as possible. The histopathological results of the cavities prepared by Er: YAG Laser revealed the early proliferation of the odontoblasts in the odontoblastic layer of the coronal part of the pulp which led to the early formation of the reparative dentin in comparison to those prepared by conventional method. It can be concluded that the use of the Er: YAG laser in class I cavity preparation has proved to be an efficient technique in comparison to the conventional cavity preparation.

### Introduction

Dental pulp is restricted by inflexible walls with a confined circulation supplied by an arteriole through a narrow apical foramen. Circulation disorders determine the reversibility limit for pulp lesions and are precipitated by

physical, chemical, thermal, or biologic stimuli (Lefkowitz W, et al, 1958). High-speed rotary cutting instruments allow mineralized tissues to be prepared with minimal effort and, therefore, are efficient. However, if these instruments are used inappropriately, the dental pulp may be irreparably damaged. Heat production during

tooth preparation and mechanical damage are major sources of trauma (Zach L , Cohen G., 1965).

Also dental treatment is generally recognized as a painful procedure. The introduction of local anesthesia has reduced the pain, but the fear remains, especially with respect to the injection. The noise and the vibrations of mechanical drilling during preparation also make the conventional preparation technique unpleasant to the patient (Hibst R., Keller U, 1997).

Due to these undesirable effects, it is not surprising that concentrated efforts have focused on new techniques such as lasers for painless caries removal. Research on the medical and dental applications of laser got momentum when the ruby laser was developed<sup>4</sup> and was tried in dentistry (Goldman L, et al, 1965, Goldman L, et al, 1964 Stern RH, Sognaes RF, 1964 and Stern RH, et al, 1969)

The advances in laser research identified the clinically useful laser-wavelengths, the physical and technical parameters to be set in such devices and the provision for water cooling (Visuri SR, et al, 1996). These developments led to a new generation of laser devices with improved efficacy and diminished heat distribution for application on dental hard tissues (P.N. Ramachandran N., 2003).

The Er: YAG laser has a wavelength of 2.94  $\mu\text{m}$  which represents the absorption peak of water. As such, the laser energy is more or less completely absorbed by water molecules in the enamel and dentine resulting in micro-explosions and vaporization of the hard tissues (ablation) (Keller U, Hibst R., 1989).

Reduction of pain during cavity-preparation and caries-removal has been an expected benefit of laser usage. Further, for clinical use, the 2.94  $\mu\text{m}$  radiation is known to have no mutagenic or carcinogenic effects (Walsh JT, et al, 1989). These properties have been suggested to make Er: YAG laser suitable for cavity-preparations in permanent and more ideally in primary teeth (Takamori K., 2000).

### Aims of the Study

This study aims is to evaluate the histopathologic changes of the dentin and pulp responses to the use of Er: YAG laser ablation for class I cavity preparation in vivo, and to compare between the histopathological changes

of the dentin and pulp response to Er: YAG laser ablation and the conventional class I cavity preparation by tooth drilling in vivo.

### Materials and Methods

Thirty five sound human (Age 14-24 years) upper and lower first premolar teeth (which were needed to be extracted for orthodontic purposes) were used in the present study. According to the method of cavity preparation the teeth were grouped into three groups, as following:

*Group 1(Control group):* Consists of 7 sound teeth without cavity preparation.

*Group2 (Conventional bur cavity preparation group):* Consists of 14 teeth were subdivided as following:

A. 7 teeth were extracted after two days after cavity preparation.

B. 7 teeth were extracted after twenty-one days after cavity preparation.

*Group 3(Er: YAG laser cavity preparation group):* Consists of 14 teeth were subdivided as following:

A. 7 teeth were extracted after two days after cavity preparation.

B. 7 teeth were extracted after twenty-one days after cavity preparation.

Er:YAG Laser device (KaVo KEY<sup>®</sup> Laser 3 (1243); Bibrach Riss, Germany) emits radiation at wavelength of 2940 nm in the infrared region, classified as a class IV laser according to the (ANSI) classification and is supplied with its protective eyewear. The pulse energy ranges from 10 to 600 mJ and it is adjustable in the range of 10-200 mJ in 20 mJ steps and 200-600 mJ in 50mJ steps. The pulse repetition rate (PRR\*) is also adjustable from 1-25 Hz and the pulse duration ranges from 200 to 700 $\mu\text{s}$ . The cavity preparation was done with distilled water cooling irrigation spray merging from the jet nozzle in the head of the 2060 laser hand-piece.

The laser irradiation was performed in a non-contact mode with a focused beam of (energy density =155985.9 mJ/cm<sup>2</sup>, energy= 600 mJ and a PRRs= 6 Hz for enamel preparation) and (energy density=64994.151 mJ/cm<sup>2</sup>, energy= 250 mJ and a PRRs=4 Hz for dentin preparation) with a spot diameter of 0.7mm at 12-15 mm distance and at right angle to the tooth surface as possible (according to the manufacturer recommendations).

Class I cavity of 4mm length (mesiodistally), 2mm width (buccolingually), and 4mm ( $\pm 0.5$ ) depth was prepared on the occlusal surface of the teeth of both group 2 and 3. Then the cavities were filled with Zinc-oxide-eugenol (Dori Dent, Austria).

Immediately after extraction the teeth were gently rinsed in running cold water, fixed in formaldehyde solution (10%) for 2 days at room temperature and put in 1% nitric acid for about  $10 \pm 2$  days. After the decalcification, the teeth were cut bucco-lingually (longitudinal section) into two halves; mesial and distal.

Later the then mounted in wax. The paraffin embedded tissue were cut with rotary microtome (Germany) to sections of five microns, mounted on glass slides, and stained with routine Harris Hematoxyline-Eosin stain (H&E). The slides were examined under light microscope equipped with photo-automatic unit.

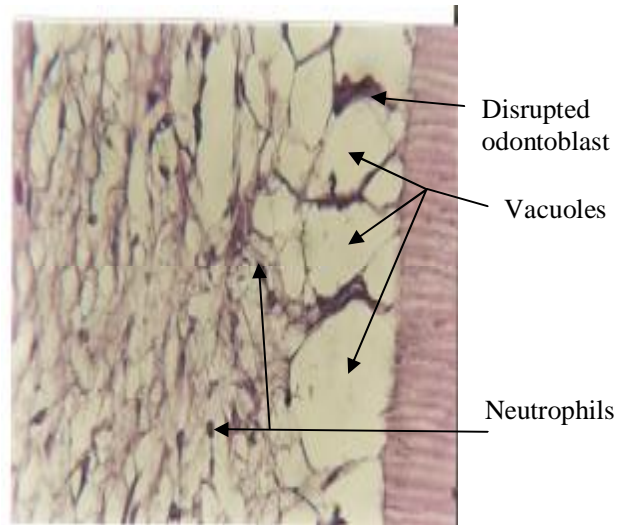
### Results

The clinical observation of this study showed that the time of cavity preparation of both groups 2 and 3 was equal. The facilities of access with laser hand-piece were good with limitation of difficulties. The patients were more comfort with laser than the conventional method and the whole laser work was done with no need for local anesthetic solution.

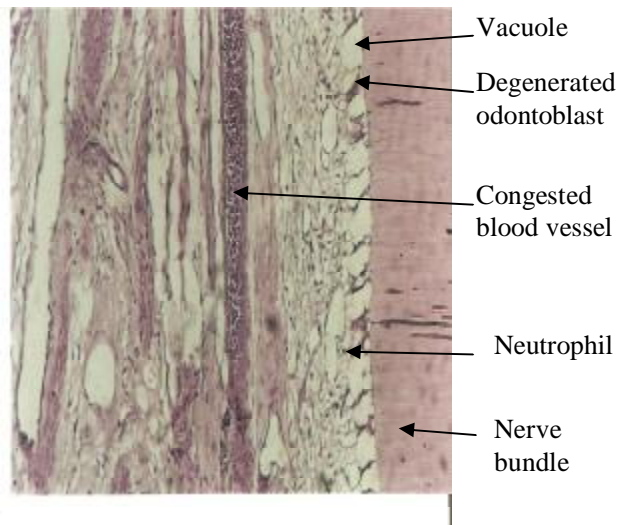
The preparations by the Er: YAG laser gives a characteristically chalky surface appearance. The post-operative clinical condition of the teeth was uneventful in all cases belonging to both groups 2 and 3 during the 2 and 21 days observation periods. Clinical complications such as pain and signs of inflammation or infections were not observed throughout the follow-up periods. The histopathological results revealed the microscopical view of the pulp and dentin.

#### Results of group 2 subgroup A

The histological findings of the coronal part of the pulp showed signs of mild reactions, isruption of the odontoblastic layer and small vacuoles appeared between them. Capillaries in the irradiated area were dilated (hyperemia), as shown in Figure (1): (A and B)



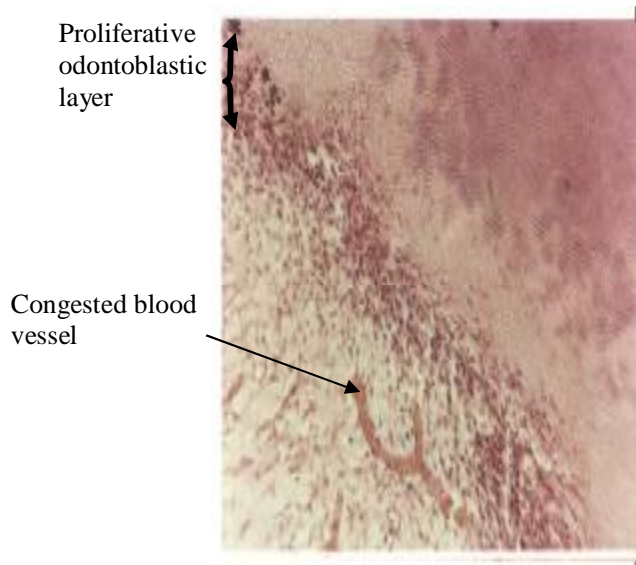
**Fig. (1-A):** Photomicroscopic picture (upper left first premolar of 17 years old female patient) at 2 days after cavity preparation by a high-speed drill. (H&E X40.)



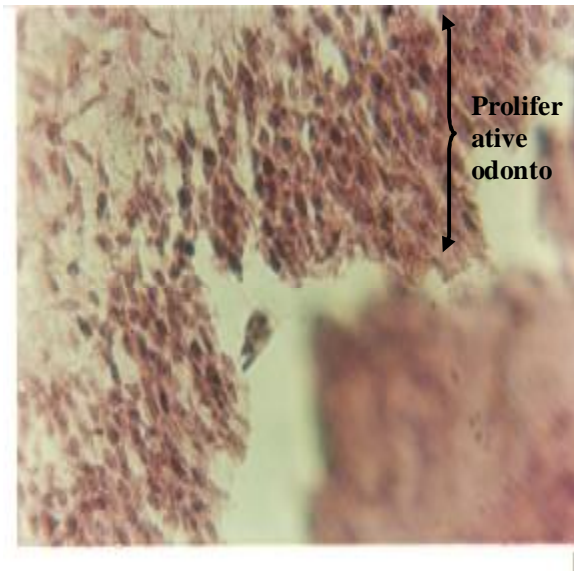
**Fig. (1-B):** Photomicroscopic picture (upper left first premolar of 17 years old female patient) at 2 days after cavity preparation by a high-speed drill. (H&E X20).

#### Results of group 3 subgroup A:

All the cases (patients) of this group except the first case (patient) revealed a proliferation of the odontoblasts in the odontoblastic layer, and the blood vessels appeared congested (hyperemia), as shown in Figure (2):(A and B). No other signs of inflammation were observed.



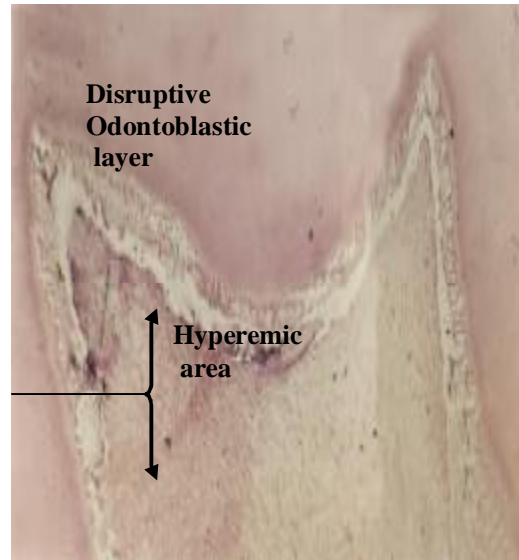
**Fig. (2-A):** Photomicroscopic picture (upper left first premolar of 16 years old female patient) at 2 days after cavity preparation by Er: YAG laser. (H & E X20).



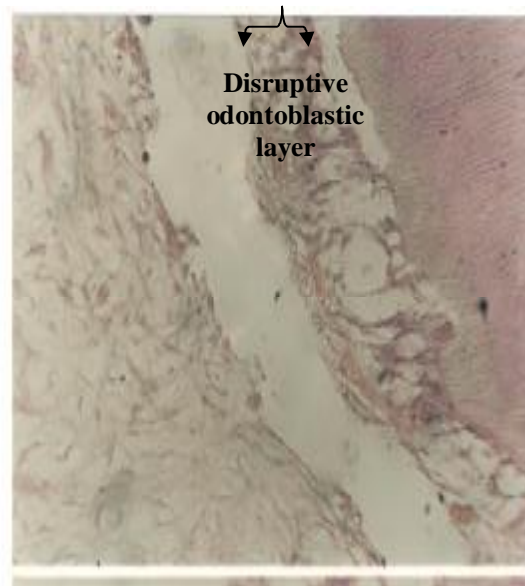
**Fig. (2-B):** Photomicroscopic picture (upper left first premolar of 16 years old female patient) at 2 days after cavity preparation by Er: YAG laser. (H&E X40)

In the first case (patient) of this group the histological findings revealed in addition to the disruption of the odontoblastic layer and the appearance of vacuoles between them, a severe hyperemia, congested blood vessels, and

inflammatory cells infiltration were distinctly observed; as seen in Figure (3 and 4)



**Fig. (3):** Photomicroscopic picture (lower right first premolar of 16 years old female patient) at 2 days after cavity preparation by Er: YAG laser. (H&E X20)



**Fig. (4):** Photomicroscopic picture (lower right first premolar of 16 years old female patient) at 2 days after cavity preparation by Er: YAG laser. (H&E X40)

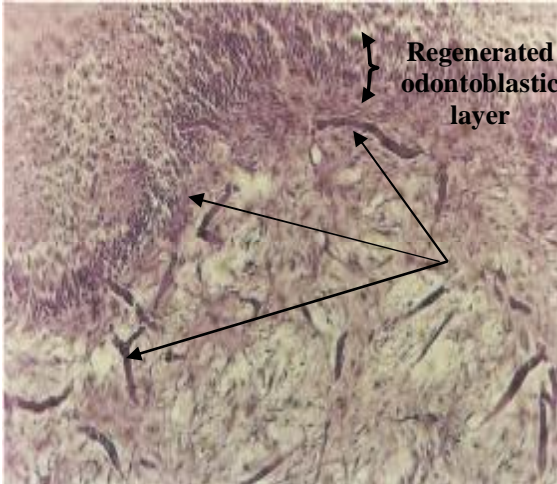
The results of subgroup A of group 2 and group 3 is shown in Table (1). Table (1):



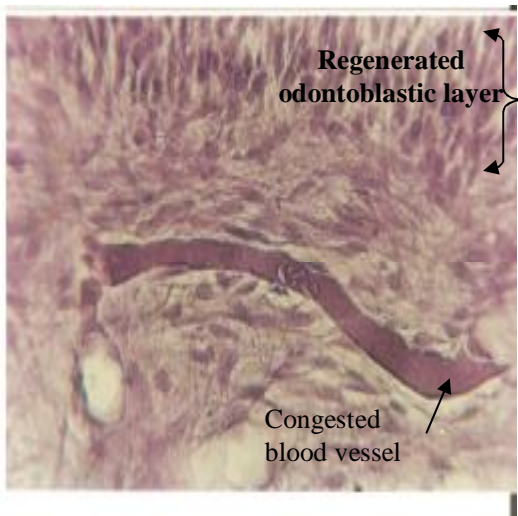
Histopathological criteria of the pulp at 2 days after cavity preparation.

**Results of group 2 subgroup B:**

The results of group 2 subgroup B showed regeneration in the odontoblastic layer, the presence of the vacuoles between the odontoblasts but less in number and size than that present in subgroup A, and mild hyperemia; as shown in Figure (5):(A and B).



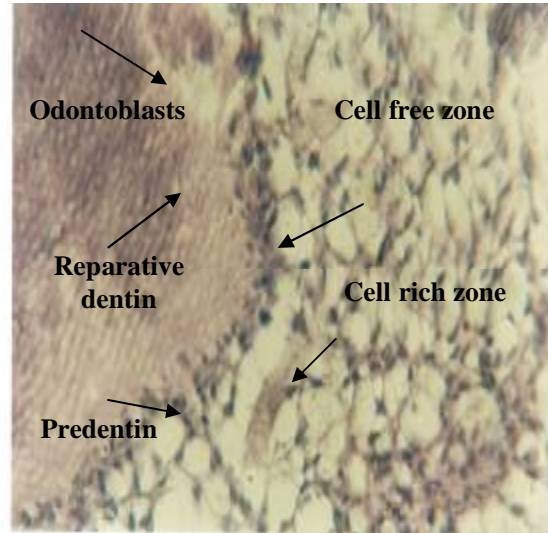
**Fig. (5-A):** Photomicroscopic picture (upper left first premolar of 17 years old male patient) at 21 days after cavity preparation by high speed drill. (H&E X20)



**Fig. (5-B):** Microphotograph picture (upper left first premolar of 17 years old male patient) at 21 days after cavity preparation by high speed drill. (H&E X40.)

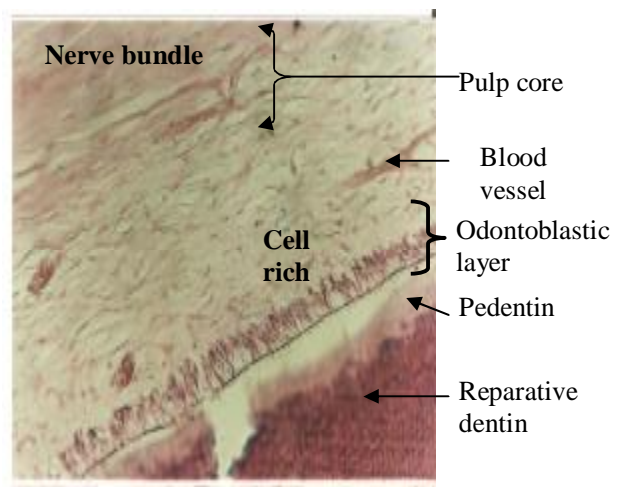
**Results of group 3 subgroup B:**

These results showed that the segment of the peripheral pulp immediately subjacent to the floor of the prepared cavity revealed a formation of reparative dentin. The reparative dentin was easily identified by its stainability to ematoxylin and eosin which differed from the primary dentin; as shown in Figure 6.



**Fig. (6):** Photomicrograph picture (upper left first premolar of 19 years old female patient) at 21 days cavity preparation by Er: YAG laser. (H&E X40.)

Other histological findings looked normal no hyperemia and no signs of inflammation; as seen in Figure 7.



**Fig. (7):** Photomicrograph picture (upper left first premolar of 16 years old female patient) at 21 days cavity preparation by Er: YAG laser. (H&E X20)

**Results of subgroup B of group 2 and group 3:**

The results of subgroup B of group 2 and group 3 are shown in table 2.

**Table (2):** Histopathological criteria of the pulp and dentin at 21 days after cavity preparation.

Histopathological Criteria of the pulp	Group 2	Group 3
Odontoblastic layer	disruption and vacuoles formation	proliferation
Cell-rich zone	inflammatory cells infiltration	fibroblast proliferation
Vascularity	Hyperemia	Hyperemia

**Discussion and Conclusions**

It is well known that cavity preparation induces certain acute morphological changes in the dental pulp and the use of rotary instrument considered the most damaging insult to pulp (due to excessive heat generation by friction of the rotary instrument) (James B. S., et al, 2006).

Miserendino et al. in 1998 reported that cavity preparation with the erbium lasers (seen from histology slides) did not show no immediate, short-term, nor long-term negative effects compared with the conventional dental drill (Miserendino L, C. C., 1998). Although pain may be reduced during the conventional method by local anesthesia, fear of the needle, noise and vibration of mechanical preparation remains causes of discomfort.

The mechanisms of pain reduction in cavity preparation with Er: YAG laser (in which no need for the use of local anesthetic solution) could be due to minimal thermal damage to the dental pulp. This come into agreement with Marcer (Marcer C., 1996) and Hussein (Hussein A., 2006). The chalky whitish surface demonstrated on the enamel surfaces of the Er:YAG laser cavities may be a surface dehydration caused by the ablation process, this come into agreement with Deng et al. in 2004 (Deng Y. et al, 2004).

**After 2 days of cavity preparation:**

The dental pulp as well as dentin is known to undergo remarkable morphological changes

after cavity preparation. These changes in the pulp can be explained by the fact that the dentin is presumably traversed in its full thickness by the cytoplasmic processes of odontoblasts. This comes into agreement with Gunji and Kobayashi (Gunji, T. S., Kobayashi 1983) and Sigal et al. (Sigal, M. J., et al, 1984 and Sigal, M. J., et al, 1984). When the surface layer of the dentin is drilled, the processes of odontoblasts are mechanically injured, leading to the degeneration of their cell bodies and empty spaces (vacuoles) formation in stead. This come into agreement with Carter et al, (Carter JM., et al, 1983)

While in the Er: YAG laser group (except for the first patient) the proliferative odontoblasts that derived from the proliferative fibroblasts were the most important features. In other words these results showed that the Er: YAG laser led to initiate and complete of pulpal repair earlier than the high-speed drill. In the present study it was found that the Er: YAG laser irradiation tended to cause more and earlier fibroblast proliferation than the high-speed drill group. This result was similar to those reported by Sekine et al. (Sekine Y, 1984) and Cozean et al. (Cozean C, et al, 1997). In Er: YAG laser group, the earlier fibroblast proliferation (which gives rise to earlier odontoblast proliferation) may be accused by an earlier increase and then decrease in *Calcitonin gene-related peptide* CGRP (which is reported to take part in inducing the proliferation of human and rat pulp fibroblasts in vitro (P.N. Ramachandran N., 2003 and Takamori K., 2000). level than in the high-speed drill group. This comes into agreement with that reported by Takamori (Takamori K., 2000) and Nair et al. (P.N. Ramachandran N., 2003).

The earlier increase and then decrease in CGRP level in the Er: YAG laser irradiation group may be attributed to the biostimulation effect of the pilot beam (Ga-Al-As 655 nm diode laser) that emitted in association with the Er: YAG laser beam. This comes into agreement with Van et al. (Van B. HH, 1992), Ozawa et al. (Ozawa Y, et al, 1998), and Hossein et al. (Hossein B., 2005). Actually the mechanism of action between conventional hand-piece and Er: YAG laser hand-piece is completely different. That's to say conventional hand-piece removes the hard tissue substance by friction of the rotating bur while Er: YAG laser ablate hard tissue by mean of photothermal (photoablation) (as mentioned before).

The maximum temperature variation for Er: YAG laser and conventional bur were 2°C and 4°C respectively in Class V cavity of 2mm depth (Cavalcanti BN., et al, 2003).

This variance in temperature between the Er: YAG laser group and conventional bur group may lead to variance in histopathological observations between the two groups.

The water cooling of the laser system helped to reduce the heat distribution so that the rise in pulpal temperature did not reach the critically damaging level of 5.5°C.

In laser group the general absence of damaging thermal effects on the pulp was most likely due to the particular wavelength of the laser, the characteristic interaction (photothermal interaction mechanism) between the laser and the hard tissues of the teeth, the specified energy settings, and the provision for water-cooling.

*Hyperemia* that resulted in subgroup A of both groups (2 and 3) was transient and localized to the pulp adjacent to the cavity preparation and should be considered as a normal physiologic response, this come into agreement with Miserendino et al. (Miserendino L, C. C., 1998).

**For the first patient** of group3 subgroup A (lower right first premolar) of the Er: YAG laser group, due to lack of the previous experience, the irradiation time was the longest for this patient. This made the histopathological observations seem to be different. The other reason is that regarding the remaining dentin thickness. It is known that this thickness has a decisive role in the generation of the intrapulpal temperature (lower premolar teeth characterized with high pulp level so lower dentin thickness than upper premolars). In other words with thinner dentin temperature inside the pulp chamber will be higher this come into agreement with Lauer et al. (Lauer, H. C., et al, 1990) and Nair et al. (P.N. Ramachandran N., 2003).

#### **After 21 days of cavity preparation:**

The formation of reparative dentin after 21 days after cavity preparation was observed in the laser group not in the high-speed drill group. This was probably because fibroblast and odontoblast proliferation (which are responsible for the secretion of the reparative dentin) occurred earlier in the Er: YAG laser group than in the high-speed drill group.

The formation of reparative dentin occurred as a result of organization of the area of blood extravasation. Reparative dentin is thought to have been formed by collagen, noncollagenous protein, growth factors, etc., and secreted by the cells (odontoblasts) that multiplied in the damaged pulp tissue.

The time at which the reparative dentin formation was observed in this study was to some extent similar to that reported by Keller and Hibst (Keller U, Hibst R., 1991) (3 to 5 weeks after cavity preparation by Er: YAG laser irradiation in dogs pulp), Sekine et al, (Sekine Y, 1984) (28 days after cavity preparation by Er: YAG laser irradiation in dogs pulp), and Takamori (Takamori K., 2000) (10-14 days after cavity preparation by Er: YAG laser irradiation in rats pulp).

This means that the Er: YAG laser leads to pulpal repair earlier than the high-speed drill. This result comes into agreement with Takizawa (Takizawa M., 1996) , Takano et al, (Takano T, et al, 1997) , Calland et al. (Calland JW, et al, 1997) , and Jayawardena et al. (Jayanetti Asiri Jayawardena, et al, 2001).

Lastly it can be concluded that the Er: YAG laser cavity preparation has proved to be an efficient technique in comparison to the conventional bur cavity preparation, regarding the histopathological changes after class I cavity preparations in premolar teeth. The Er: YAG laser (with the parameter of 15598.59 mJ/cm<sup>2</sup>, 600mJ, and 6Hz for enamel preparation and 64994.151 mJ/cm<sup>2</sup>, 250mJ, and 4Hz for dentin preparation) tended to cause earlier fibroblast and odontoblast proliferation than the high-speed drill which led to pulpal repair and reparative dentin formation earlier than the high-speed drill.

#### **References**

- Calland JW, Harris SE, Carnes DL. (1997): Human pulp cells respond to calcitonin gene-related peptide in vitro. J Endod.; 23:85-9.
- Carter JM., Sorensen SE., Johnson RR., (1983): Punch shear testing of extracted vital and endodontically treated teeth, J Biomech, 16, 814.
- Cavalcanti BN., Lage-Marques JL., Rode SM., (2003): Pulpal temperature increases with Er:

- YAG laser and high-speed handpieces, *J Prosthet Dent.*, , 90, 447-451.
- Cozean C, Arcoria CJ, Pelagalli J, Powell GL. (1997): Dentistry for the 21<sup>st</sup> century. Er: YAG laser for teeth. *J Am Dent Assoc*; 128:1080-1087.
- Deng Ying, G.K. Chuah, Chin-Ying S. Hsu. (2004): Effect of Er: YAG laser and organic matrix on porosity changes in human enamel. *J. of Dent.* (32), 41-46.
- Goldman L, Gray JA, Goldman J, Goldman B, Meyer R. Effect of laser beam impacts on teeth. *J Am Dent Assoc* 1965; 70:601-606.
- Goldman L, Honbry P, Meyer R, Goldman B. (1964): Impact of the laser on dental caries. *Nature*; 203:417.
- Gunji, T. and S. Kobayashi. (1983): Distribution and organization of odontoblast processes in human dentin e. *Arch. Histol. Jap.* 46: 213-219.
- Hibst R., Keller U. (1997): Effect of Er:Yag laser in caries treatment: A clinical pilot study. *Laser in Surg and Med.*; 20:32-38.
- Hossein B., Masoud S., Hmid G. (2005): The effect of low level laser irradiation on human embryonic stem cells. *Yakhteh Medical Journal*, 7, No 2, summer, 62-67.
- Hussein A. (2006): Applications of Lasers in Dentistry: A Review Article. *Archives of Orofacial Sciences*; 1: 1-4.
- James B. Summit, J. William Robbins, Richard S. Schwartz., (2006): Fundamentals of operative dentistry: A contemporary approach.
- Jayanetti A. J., Junji K., Kayoko M., and Yuzo T., (2001): Pulpal response to exposure with Er: YAG laser. *Oral Surg. Oral Med. Oral Path. Endod.* 91. (222-229).
- Keller U, Hibst R. (1989): Experimental studies of the application of Er: YAG laser on dental hard substances. II Light microscopic and SEM investigations. *Lasers Surg Med*; 9:345-351.
- Keller U, Hibst R. (1991): Tooth pulp reaction following Er: YAG laser application: SPIE, lasers in orthopedic, dental, and veterinary medicine; 1424:127-33.
- Lauer, H. C., Kraft, E., Rothlauf, W., and Zwingers, T., (1990): Effects of temperature of cooling water during high-speed and ultrahigh speed tooth preparation. *J. Prosthet. Dent.*, , 63:407-414.
- Lefkowitz W, Robinson HBG, Postle HH. Pulp response to cavity preparation. *J Prosthet Dent* 1958; 8:315-24.
- Marcer C., (1996): Laser in dentistry. A review part 2: Diagnosis, Treatment and Research. *Dental Update*, , 4, 120-124.
- Miserendino L, Cozean C. (1998): Histological results following in-vivo cavity preparation with an Er: YAG laser. *Lasers in dentistry. Proc SPIE*; 3248:46-50.
- Ozawa Y, Shimizo N, Kariva G, Abiko Y. (1998): Low-energy laser irradiation stimulates bone nodule formation at early stages of cell culture in rat calvarial cells. *Official Journal of the International Bone and Mineral Society*, April; 4: 347-354.
- P.N. Ramachandran N., Marc M.B., Hans-Ulrich L., and Gerold K.H E . (2003): Pulpal response to Er:YAG laser drilling of dentine in healthy human third molars. *laser in surgery and medicine*; 32:203-209.
- Sekine Y, Ebihara A, Takeda A, Suda H. (1994): Pulpal reaction in dog following cavity preparation by Er:YAG laser. *SPIE* 159-67.
- Sigal, M. J., J. E. Aubin, A. R. Ten Cate and S. Pitaru. (1984a): The odontoblast process extends to the dentinoenamel junction: an immunocytochemical study of rat dentine. *J. Histochem. Cytochem.* 32: 872-877.
- Sigal, M. J., S. Pitaru, J. E. Aubin and A. R. Ten Cate. (1984b): A combined scanning electron microscopy and immunofluorescence study demonstrating that the odontoblast process extends to the dentinoenamel junction in human teeth. *Anat. Rec.* 210: 453-462.
- Stern RH, Renger HL, Howell FV. (1969): Laser effects on vital dental pulps. *Br Dent J*; 127:26-28.
- Stern RH, Sognnaes RF. (1964): Laser beam effect on dental hard tissue. *J Dent Res*; 43:873.
- Takamori K. (2000): A histopathological and immunohistochemical study of dental pulp and pulpal nerve fibers in rats after the cavity preparation using Er: YAG laser. *J Endod*; 26:95-99.
- Takano T, Ishimaru K, Takamizu M, Enatsu K, Sugahara N, Kohno A. (1997): Study on histopathological effect of Er:YAG laser on dental pulp. *Jpn J Conserv Dent*; 40:1147-53 (in Japanese).



- Takizawa M. (1996): A study on Er: YAG laser ablation for dental hard substances. Jpn J Conserv Dent; 39:1089-128 (in Japanese).
- Van Breugel HH, Bar PR. (1992): Power density and exposure time of He-Ne laser irradiation are more important than total energy dose in photobiomodulation of human fibroblasts in vitro. Laser Surg Med; 12: 528-537.
- Visuri SR, Walsh JT, Wigdor HA. (1996): Erbium laser ablation of dental hard tissues: Effect of water cooling. Laser Surg Med; 18:294-300.
- Walsh JT, Flotte TJ, Deutsch TF. Er: YAG laser ablation of tissue. (1989): Effect of pulse duration and tissue type on thermal damage. Lasers Surg Med; 9:314-326.
- Zach L, Cohen G., Pulp response to externally applied heat, Oral Surg Oral Med Oral Pathol, 1965, 19:515-30.

## دراسة نسيجية مقارنة لاستجابة العاج واللب السني لفعالية تحضير الحفرة السنية بواسطة ليزر الايريبيوم-ياك والطريقة التقليدية: محاولة في داخل الجسم البشري.

مها وليد الغزالي<sup>(1)</sup> علي شكر محمود<sup>(2)</sup> لحاظ محمد العزاوي<sup>(2)</sup> رائد كامل جرجيس<sup>(3)</sup>

(1) مركز الرصافة الطبي التخصصي، وزارة الصحة، بغداد، العراق

(2) معهد الليزر للدراسات العليا، جامعة بغداد، بغداد، العراق

(3) مركز العلوية التخصصي للأسنان، وزارة الصحة، بغداد، العراق

**الخلاصة**

الهدف من هذه الدراسة هو تحديد فعالية التحضير السني للحفرة السنية من النوع الاول بواسطة ليزر الايريبيوم-ياك (2940 نانو ميتر والطول الموجي يقع في منطقة تحت الحمراء من الطيف الضوئي) بالمقارنة مع الطريقة التقليدية و تأثيرها على الانسجة داخل اللب السني وعاج السن في دراسة سريرية. أختيرت عينة لهذه الدراسة مكونة من خمس و ثلاثين سن خالية من التسوس من الاسنان قبل الطواحن بحاجة لان تقلع لاحقا لتقويم الاسنان. تم تقسيم العينات الى ثلاث مجموعات رئيسية: المجموعة الاولى تمثل النموذج النسيجي للأسنان السليمة الخالية من الحفر السنية و المكونة من سبعة اسنان. المجموعة الثانية تمثل النموذج النسيجي للأسنان ذات التحضير السني بواسطة الطريقة التقليدية و المكونة من اربعة عشر سنا. المجموعة الثالثة تمثل النموذج النسيجي للأسنان ذات التحضير السني بواسطة ليزر الايريبيوم-ياك و المكونة من اربعة عشر سنا. تم تقسيم المجموعتين الثانية والثالثة اعلاه الى مجموعتين فرعيتين متساويتين مكونة من سبعة عينات لكل مجموعة و تم تحضير حفرة سنية قياسية من النوع الاول. المجموعة A التي تمثل مجموعة الاسنان التي تم قلعها بعد يومين من تحضير الحفرة السنية المجموعة B التي تمثل مجموعة الاسنان التي تم قلعها بعد واحد وعشرون يوما. في هذه الدراسة كل العينات قيمت نسيجيا وفحصت منفصلة تحت المايكروسكوب الضوئي (ستيريو). الأسنان قطعت طوليا لفحصها وتقويمها تحت المايكروسكوب لدراسة التغيرات التي طرأت على نسيج عاج ولب السن كرد فعل لتحضير الحفرة السنية بالطريقتين المذكورتين اعلاه والمقارنة بينهما. عند التحليل للصور المجهرية المتعلقة بالمقارنة فيما بين المجموعات الرئيسية والفرعية، نتائج الدراسة أظهرت وجود اختلافات بين المجموعتين الرئيسية الثانية والثالثة بمجاميعهما الفرعية. افضل النتائج كانت للمجموعة الرئيسية الثالثة بفرعها A و B والتي تمثل عينات تم تحضيرها بواسطة ليزر الايريبيوم-ياك، الطول الموجي (2940 نانو متر). يستنتج من الدراسة أن استخدام ليزر الايريبيوم-ياك في تحضير الحفرة السنية من النوع الاول كان افضل من الطريقة التقليدية في تأثيره على انسجة اللب السني وعاج السن.