



Spider Veins Treatment using 1064 nm Long-Pulse Nd:YAG Laser

Mardukh S. Abd ⁽¹⁾ Lutfi G. Awazli ⁽²⁾ and Najim A. Issa ⁽³⁾

(1)Ministry of Health, Al-Amiryah General Hospital, Al-Anbar, Iraq

(2)Institute of laser for postgraduate studies, university of Baghdad, Baghdad, Iraq

(3)Ministry of Health, AL Elweyia Maternity Hospital, Baghdad, Iraq

(Received 1 February 2018 ; accepted 3 September 2018)

Abstract: Introduction: spider veins are clusters of Ectatic venules & are common finding on the lower limbs generally believed to be caused by multiple factors, including genetic predisposition, hormonal factors, gravity, occupation, pregnancy, becoming increasingly apparent with age, and trauma. Therapeutic options include sclerotherapy, surgical procedures, and treatment with different laser systems. **Objectives:** The purpose of the study was to evaluate the efficacy and safety of long pulsed (Nd:YAG) laser emitting at 1064nm in the treatment of spider veins. **Patients, Materials and Methods:** This prospective study was done in the laser medicine research clinics of the Institute of laser for postgraduate Studies / University of Baghdad from September 2016 until the end of December 2016. The study included ten patients between the ages of 22 to 55 years suffered from spider veins of the lower limbs. They were treated with a long pulsed (Nd:YAG) laser in a non contact technique using the following laser parameters (wavelength 1064 nm ,energy 30-73 J, pulse duration 10-30 ms, frequency 2Hz, spot diameter 3-7mm). Laser therapy was performed on day zero and day fourteen. Clinical assessments were carried out before laser therapy and immediately after the first laser therapy, 2 weeks, 4 weeks, and 6 weeks later. **Results:** Results showed that there was a remarkable improvement for all patients after the second treatment. Six patients (60%) showed a complete disappearance of the spider veins and there was an improvement for four patients (40%) with no significant intraoperative and postoperative pain or complications, within short operative time. **Conclusion:** The long pulsed (Nd:YAG) laser (1064 nm) is an effective and safe treatment option for lower limbs spider veins.

KEY WORDS: Cutaneous Spider Veins, Long-Pulse Nd:YAG Laser , Telangiectasias

Introduction

Spider veins are clusters of Ectatic venules present in approximately 40% of women and 15% of men. More than 70% have a family history. Often, pregnancy or other hormonal influences are implicated ⁽¹⁾ (Kemal Ozyurt et al 2012). Although a primarily cosmetic problem, more than half of these vessels may become symptomatic. (Constantin Confino 2012, M.F.Stier 2008, J.BucciandJ.D.Goldberg 2006) Clinical and experimental evidence suggests that valvular incompetence leading to a rise in venous pressure and peripheral vein wall weakness in the superficial venous system is

responsible for the development of varicose veins, reticular veins, and telangiectasias, although these may not be the only mechanisms. (Arne A. Meesters 2013)

The lesions are common finding on the lower limbs and are generally believed to be caused by multiple factors, including genetic predisposition, hormonal factors, gravity, occupation, pregnancy, and trauma, becoming increasingly apparent with age.(Robertson L et al 2008)

Therapeutic options include sclerotherapy, surgical procedures, and treatment with different laser systems which become increasingly

efficacious and a convenient method for treatment. (Arne A. Meesters 2013)

Aim of the study

To study the effect and safety of a long pulsed Nd:YAG laser therapy (1064 nm) in treatment of lower limbs spider veins

Patients, Materials and Methods

Patient description: This Prospective study including 10 patients (8 females, 2 males) with symptomatic spider veins submitted to Nd:YAG

laser at laser medicine research clinics of Institute of Laser for postgraduate studies. Patients ages ranged from (22-55) years old with mean 35.3 years old (Table 1). Each patient was getting ready for the procedure after full explanation and discussion regarding the nature of the procedure, the possible advantages and disadvantages, and expected complications. At the end of discussion, each patient was asked to sign an “informed consent” indicating the agreement.

Table (1) patient description

Case no.	Gender	Age(year)	Occupation	Duration of symptom (year)
1	f	22	Student	6
2	f	29	housewife	3
3	f	35	housewife	12
4	f	45	employee	16
5	f	34	athletes	5
6	m	55	ex-officer/shop keeper	15
7	m	50	ex-solder	6
8	f	24	housewife	1
9	f	37	employee	15
10	f	22	lecturer	10

f=female, m=male

Preoperative evaluation: A case sheet was prepared to record all the necessary information. Medical and surgical histories were taken from the patients with clinical examination for each patient and underwent Doppler ultrasound to rule out deep system reflux at the saphenous junctions and in the perforating veins.

Treatment Parameters and settings used in the study: figure (1)

High peak power, long-pulse Nd:YAG laser system

Wavelength	1064 nm
Pulse duration	10-30ms
Frequency	2 Hz.
Puls Energy	30-73 j
Spot size	3- 7 mm at the level of the hand-piece

Cooling Epidermal (contact cooling to tissue by the hand piece via conductive metal plates.)

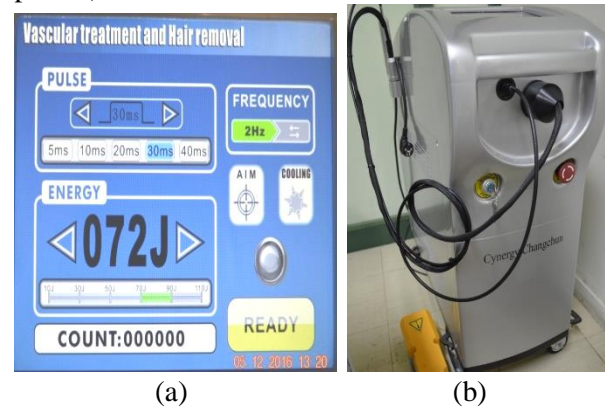


Fig. (1): (a) Laser parameters
(b) long-pulse Nd:YAG laser system

Technique

Prior to laser therapy patients asked to shave the hair from the area to be treated (if hair is present, it will absorb the laser energy and causing discomfort).

Proper eye protection for patient, physician and anyone else in the room is essential when using this laser. Figure (2)

Patients lying after having put topical anesthesia (EMLA) for an hour. A test dose was performed at the initial consultation, and thereafter patients were reviewed and treated at 3-week intervals. However, in some cases, until achieving our desired clinical results, we increased fluence after decreasing the pulse width.

In < 0,5mm leg telangiectasia, maximum fluence was increased up to 400 J/cm² with 3mm spot size at the skin surface and external skin cooling is necessary.

The average time taken for completing the procedure was (20 min.).

All patients were advised to avoid sun exposure of treated area two weeks following laser treatment in order to minimize the appearance of hyperpigmentation.



Fig.(2) goggles (a) for Nd:YAG laser operator (b) for patient

Results

The results of this study depend mainly on the clinical observation by inspection, patient complaints during operation and clinical postoperative follow-up. All procedures were performed in an outpatient setting and all patients were discharged home within one hour after treatment.

For six (60%) patients there was a disappearance of the spider veins and there was an improvement of four (40%) patients (two of them with one session of laser treatment). Vessel clearance improved with time after laser treatment and good result was observed after the second session of laser treatment. All patients tolerated the procedure.

The results are listed in Table (2).

Regarding the adverse effects, there was a mild discomfort or mild burning sensation (tolerable). There was transient hyperpigmentation & mild erosion crusting in three patients (30%). Table(3).

In almost all patients, no purpuric reaction, no blistering, no scarring or pigmentary changes were observed at the end of follow up.

There was no need for hospitalization; none of the patients encountered any significant intraoperative or postoperative complications. Patients did not require any analgesic and can resume their routine activities immediately post operatively. There was no recurrence detected during the follow up period which was 6 weeks after the laser sessions.

Table (2) Results after laser therapy

Case No.	Age(year)	Site (lower limb)	No. of session	Degree of improvement	Satisfaction%
1	22	bilateral	4	cleared	80
2	29	unilateral	3	cleared	70
3	35	bilateral	4	cleared	60
4	45	bilateral	1	improved	60
5	34	bilateral	1	improved	50
6	55	bilateral	3	cleared	80
7*	50	bilateral	2	cleared	80
8	24	bilateral	1	improved	70
9*	37	bilateral	2	cleared	80
10	22	bilateral	2	improved	80

* Response after 1st. session

Table (3) Adverse reactions

Type	Sever	Mild	Non	Worsen
Pain	-	3/10	7/10	-
Erythema	-	4/10	6/10	-
Bulla formation	-	-	10/10	-
Focal thrombosis	-	-	10/10	-
Erosion and crusting	-	3/10	7/10	-
Transient post inflammatory hyperpigmentation	1/10	2/10	7/10	-

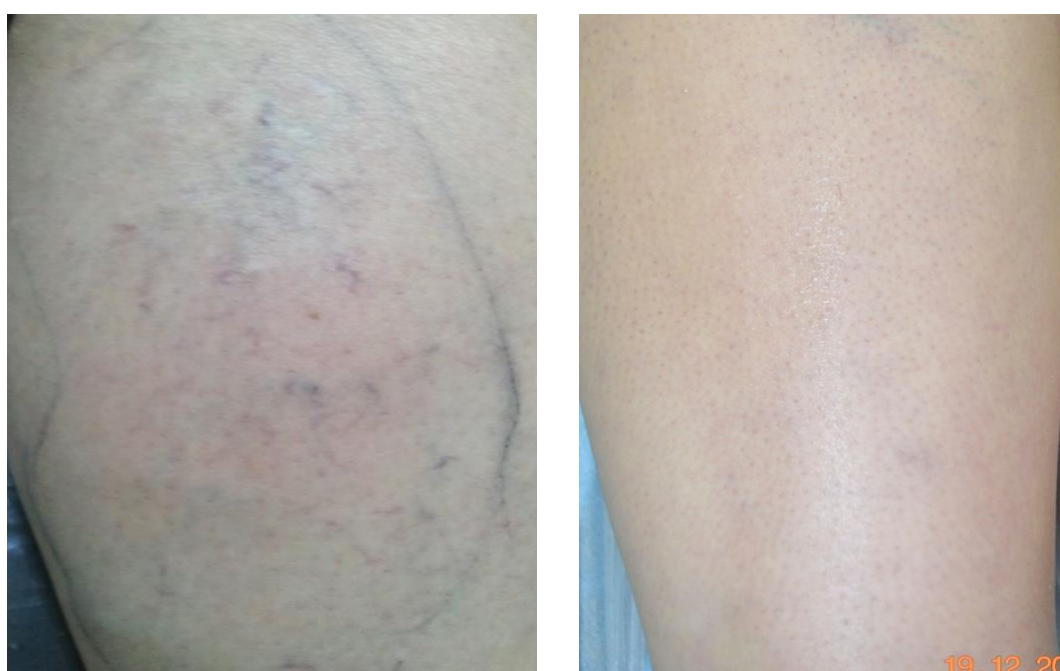

Fig. (3): spider veins of leg (a) before (b) 6 week after laser treatment

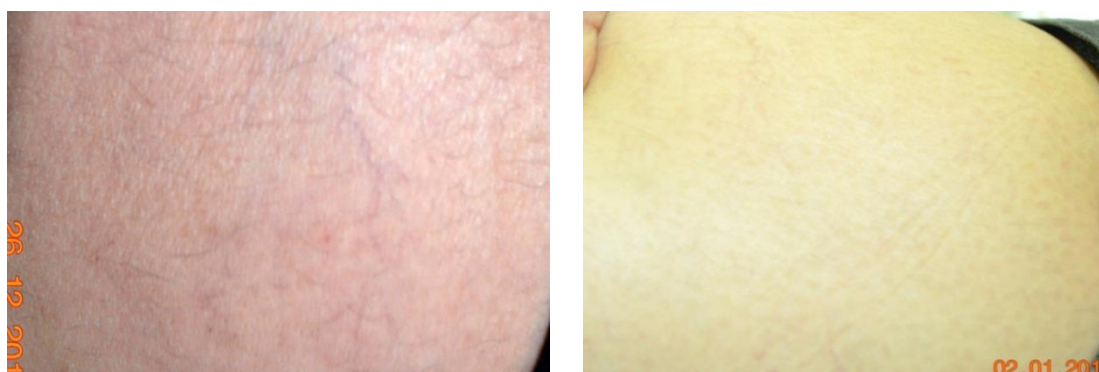

Fig. (4): spider veins of lower thigh (a) before (b) a week after laser treatment

Discussion

Laser therapy of spider lower limbs veins has become of increasing interest. In the past yellow pulsed dye lasers have been used with an improved selectivity to blue argon laser reducing the non-specific absorption by melanin. The coagulating effect of yellow laser, however is limited to a diameter of 0.4- 1mm, in the case of vessels with a diameter greater than 1mm, yellow lasers are less effective since coagulation remains incomplete. (Mccoy 1996, Joy H 2007)

Near-infrared (NIR) laser offers advantages compared to yellow dye or argon laser. The epidermal melanin absorption decreases with longer wave length. This diminishes the spread of light and allows the treatment of deeper-lying vessels. Since most spider lower limbs veins are of diameters 0.3-2 mm, with reticular veins up to 3mm, the use of NIR laser allow more successful therapy. (Constantin Confino 2012, J.BucciandJ.D.Goldberg 2006)

In one study, patients with spider leg veins were treated with the long pulse frequency-doubled (Nd): YAG laser (532nm) with a cooling device. 73% of patients had greater than 50% improvement after one treatment. 83% were seen with better results after a second treatment (U Wollina 2003, Bernstein EF 1999, Sadick Ns 2001), but unwanted side effects include pain, hyperpigmentation , scarring and blistering was happened. (Eremias 2001, McMeekin To 1999, Omura NE 2003)

Another study declared that Nd:YAG was superior to both diode laser and alexandrite in treating leg telangiectasia. Also they concluded that there were more problems with alexandrite laser than the others. (S.Eremia,C.Y.Li,andS.H.Umar 2002)

According to the scarce evidence available, the Nd:YAG laser produces better clinical results than the alexandrite and diode laser. Penetration depth is high, whereas absorption by melanin is low, making the Nd:YAG laser suitable for the treatment of larger and deeply located veins and for the treatment of patients with dark skin types.(Arne A. Meesters 2013)

The long-pulsed 1064 nm Nd:YAG laser affords greater depth of penetration than its shorter wavelength and shorter pulse-width counterparts, reaching 5 mm to 10 mm depth when used with epidermal cooling. The Nd:YAG heats the vessel more uniformly than the shorter-wavelength. This even heating

allows for more successful vessel closure. (Constantin Confino 2012, Weiss RA1999)

The Nd:YAG offers an effective option for treatment of legs veins, including reticular and spider vessels (Weiss RA1999)

Comparing the results of laser therapy of spider lower limbs veins with (injection) microsclerotherapy shows that with the using laser these advantages will be achieved: Shorter operative time, Mild or no postoperative pain, No postoperative complications detected, Shorter healing time, No postoperative compression bandages were needed. It seems that the parameters chosen for photocoagulation were safe with no apparent damage to nearby tissues and no complications detected in the treated area. (Munia MA2012, Levy JL 2004, Coles CM 2002).

Conclusions

This study concluded that the long pulse Nd: YAG laser is effective, safe and easy procedure in treatment of cutaneous spider veins with rapid lesion clearance and good final results with minimal adverse effects and low morbidity.

References

- Arne A. Meesters&Luiza H. U. Pitassi& Valeria Campos& Albert Wolkerstorfer& Christine C. Dierickx" Transcutaneous laser treatment of leg veins" Article in Lasers in Medical Science. November 2013
- Bernstein EF,Brown DB,Black J. Treatment of spider veins using a 10 millisecond pulse duration frequency –doubled Nd-YAG laser. Dermatol surg. 1999;25:316-20.
- Coles CM, Werner RS, Zelickson BD (2002) Comparative pilot study evaluating the treatment of leg veins with a long pulse ND:YAG laser and sclerotherapy. Lasers Surg Med 30:154–159.
- Constantin Confino, Betty Czajkowsky, SLT Long Pulse Nd: YAG Laser for the Treatment of Leg Veins and Benign Vascular Lesions, 2012.
- Eremias.Treatment of leg and face veins with acryogen spray variable pulse width 1064nm Nd:YAG laser. J cosmetic laser ther 2001;3:147-53.
- J.BucciandJ.D.Goldberg, “Past, present, and future: vascular lasers/light devices,” Journal

- of Cosmetic and Laser Therapy, vol. 8, no. 3, pp. 149–153, 2006.
- Joy H. Kunishige, Leonard H. Goldberg, Paul M. Friedman, Laser therapy for leg veins Clinics in Dermatology (2007)25, 454–461
- Kemal Ozyurt, Emine Colgecen, Halit Baykan, Perihan Ozturk, and Mehmet Ozkose" Treatment of Superficial Cutaneous Vascular Lesions: Experience with the Long-Pulsed 1064 nm Nd:YAG Laser "The Scientific World Journal Volume 2012, Article ID 197139, 7 pagesdoi:10.1100/2012/197139
- Levy JL, Elbahr C, Jouve E et al (2004) Comparison and sequential study of long pulsed Nd:YAG 1,064 nm laser and sclerotherapy in leg telangiectasias treatment. Lasers Surg Med 34:273–276
- M.F.Stier,S.A.Glick,andR.J.Hirsch,“Laser treatment of pediatric vascular lesions: port wine stains and hemangiomas,” Journal of the American Academy of Dermatology, vol. 58, no. 2, pp. 261–285, 2008.
- McCoys,Hanna M .An evaluation of the copper-bromide laser for treating telangiectasia.Dermatol surg. 1996;22:551-7.
- McMeekin To . Treatment of spider veins of the leg using a long –pulsed Nd : YAG laser at 532nm. J cutan laser ther 1999; 1:179-80.
- Munia MA, Wolosker N, Munia CG et al (2012) Comparison of laser versus sclerotherapy in the treatment of lower extremity telangiectases: a prospective study. Dermatol Surg 38:635–639
- Omura NE.Treatment of reticular leg veins with a 1064nm long pulsed Nd:YAG laser. J Am Acad Dermatol 2003;48:76-81.
- Robertson L, Evans C, Fowkes FG (2008) Epidemiology of chronic venous disease. Phlebology 23:103–111
- S.Eremia,C.Y.Li,andS.H.Umar,“Aside-by-side comparative study of 1064 nm Nd:Yag, 810 nm diode and 755 nm alexandrite lasers for treatment of 0.3–3mm leg veins,” Dermatologic Surgery, vol. 28, no. 3, pp. 224–230, 2002.
- Sadick Ns. Long –term results with a multiple synchronized-pulse 1064 nm Nd:YAG laser for the treatment of leg venulectases and reticular veins . Dermatol surg.2001;27:365-9.
- U Wollina. Response of spider leg veins to pulsed diode laser (810nm): a clinical , histological and remission spectroscopy study. Journal of cosmetic and laser therapy 2003; Vol5 .No 3, pages 154-162.
- Weiss RA, Weiss MA. Dermatol Surg. 1999; 25(5):399-402

علاج الاوردة العنكبوتية باستخدام الليزر نيوديميوم: ياك 1064 نانومتر ذو النبضة الطويلة

مردوخ سامي عبد علي⁽¹⁾ ، لطفي غلام عوازي⁽²⁾ ، نجم عبد عيسى الخالدي⁽³⁾

(1) وزارة الصحة، دائرة صحة الأنبار، مستشفى العامرية العام ، الأنبار، العراق

(2) معهد الليزر للدراسات العليا ، جامعة بغداد ، بغداد ، العراق

(3) وزارة الصحة، مستشفى العلوية للولادة، بغداد، العراق

الخلاصة : المقدمة: الأوردة العنكبوتية الجلدية عموماً يُعتقد بأنها ناجمة عن عوامل متعددة تشمل الاستعداد الوراثي، عوامل هرمونية، عوامل تتعلق بالمهنة، تأثير الجاذبية، الحمل، بالإضافة إلى أنها تصبح واضحة وعلى نحو متزايد مع التقدم في العمر. هناك عدة طرق لعلاج الأوردة العنكبوتية تشمل الحقن بالأبر، التدخل الجراحي، والعلاج بأنظمة الليزر المختلفة. **الهدف من الدراسة:** تقييم كفاءة وسلامة ليزر Nd:YAG ذو النبضة الطويلة في علاج الأوردة العنكبوتية. **طريقة الدراسة:** أجريت هذه الدراسة في عيادات الليزر الطبية البحثية بمعهد الليزر للدراسات العليا / جامعة بغداد للفترة من بداية شهر أيلول 2016 ولغاية نهاية شهر كانون الأول 2016. شملت الدراسة عشرة مرضى تتراوح أعمارهم ما بين 22 إلى 55 سنة وبمعدل 35.3 سنة يعانون من الأوردة العنكبوتية للأطراف السفلى حيث تم علاجهم باستخدام الليزر Nd:YAG/1064nm ذو النبضة الطويلة. **النتائج :** أظهرت النتائج تحسناً ملحوظاً للمرضى بعد جلسة العلاج الثانية واختفاء هذه الأوردة بصورة تامة في (٦٠ %) من المرضى، حيث كان الزمن اللازم لإجراء العملية قصير بالإضافة إلى أنه لم تظهر أية مضاعفات خلال فترة العملية أو بعدها ولم تسجل حالة رجوع للأوردة خلال فترة المتابعة. **الاستنتاجات :** خلصت هذه الدراسة إلى إن استعمال الليزر Nd:YAG ذو النبضة الطويلة هو إجراء فعال وآمن وسهل في علاج الأوردة العنكبوتية الجلدية و ذو نتائج مشجعة جداً وتخلو من المضاعفات.